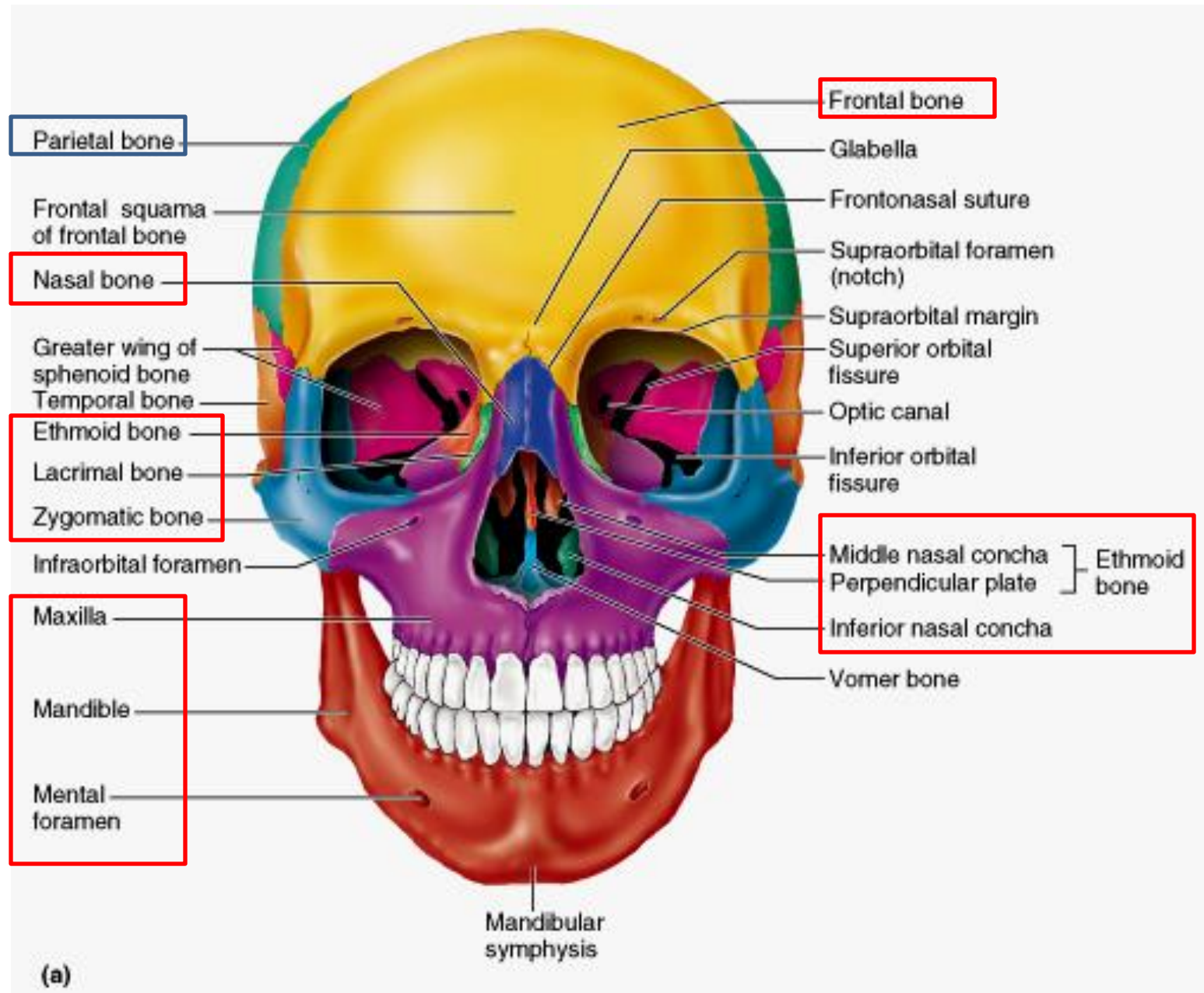
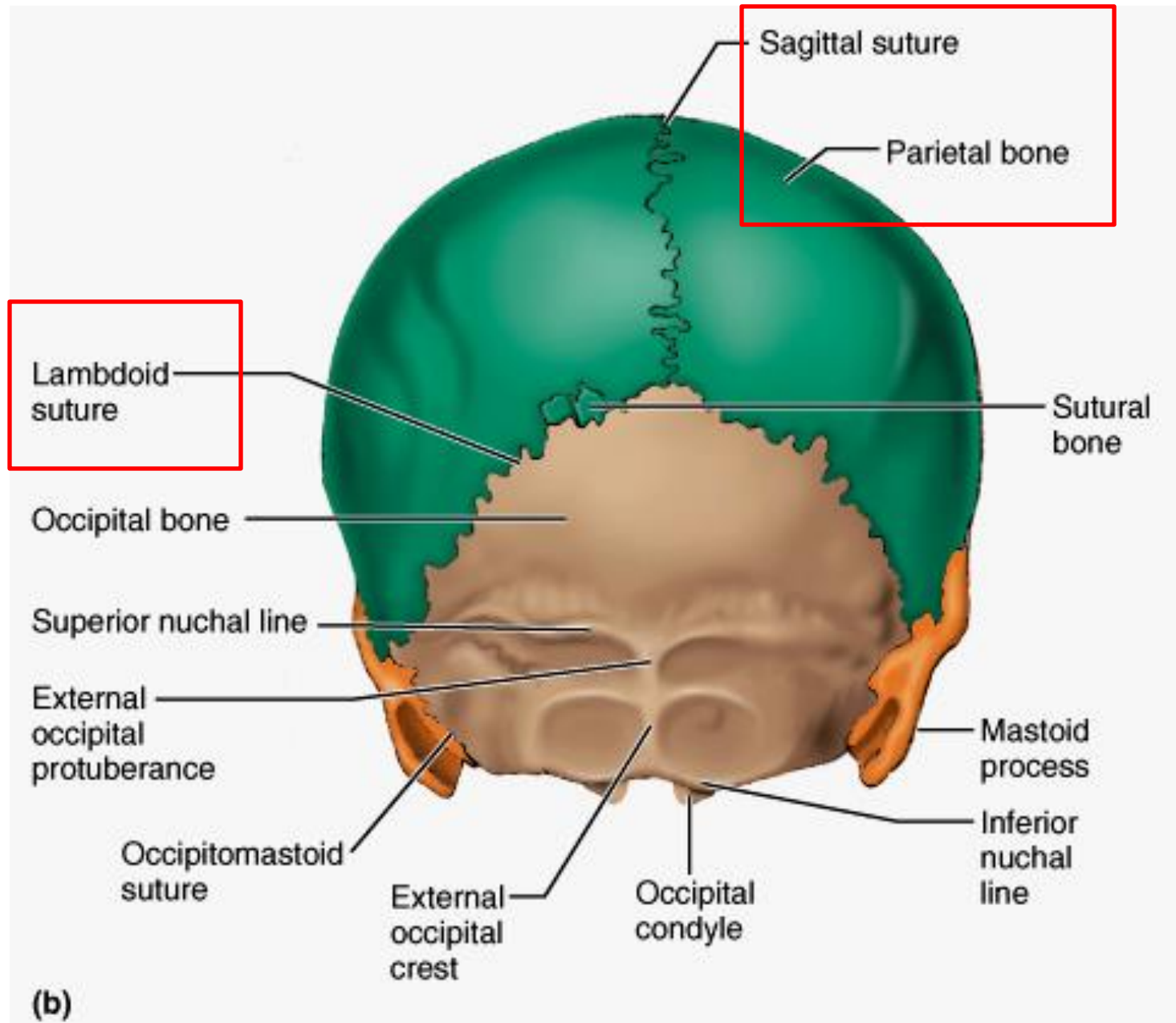
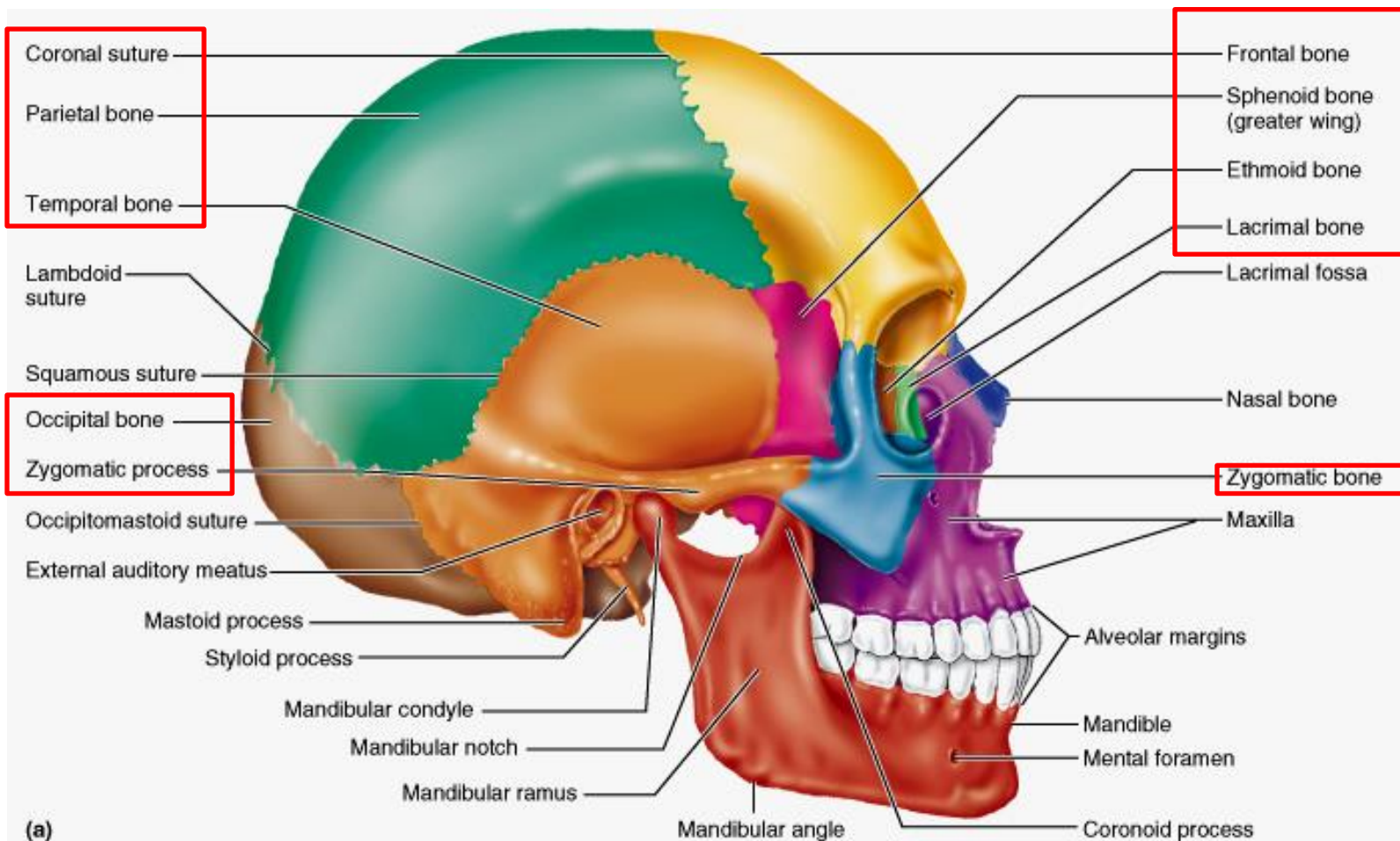
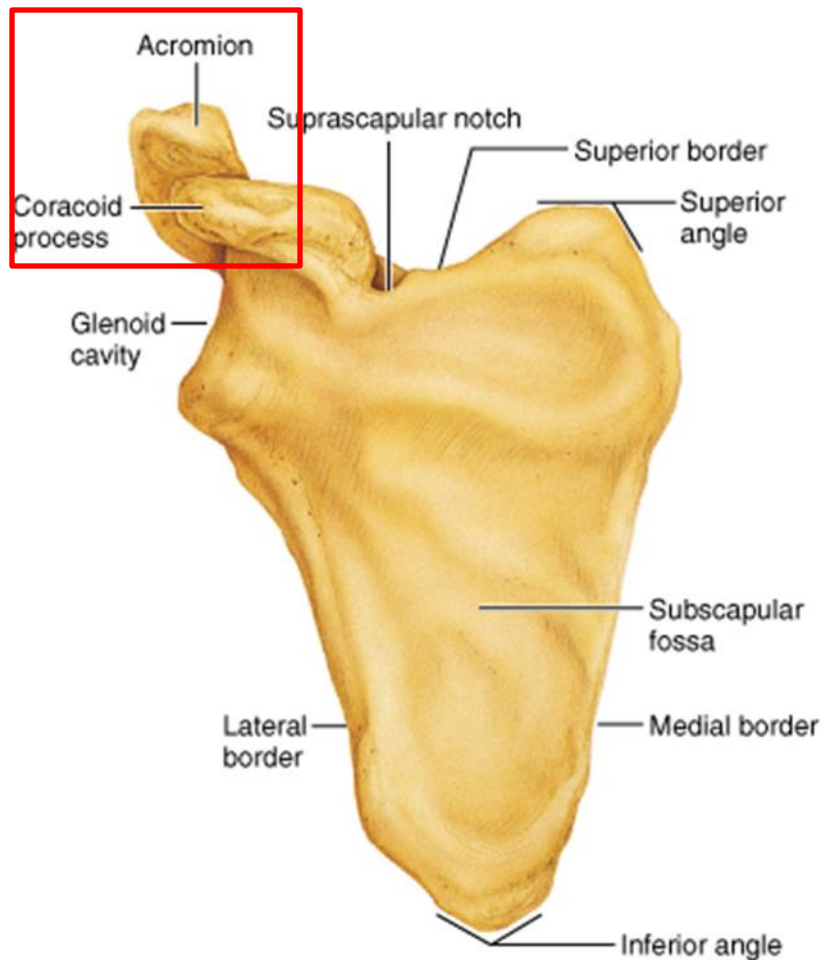


# Skeletal system

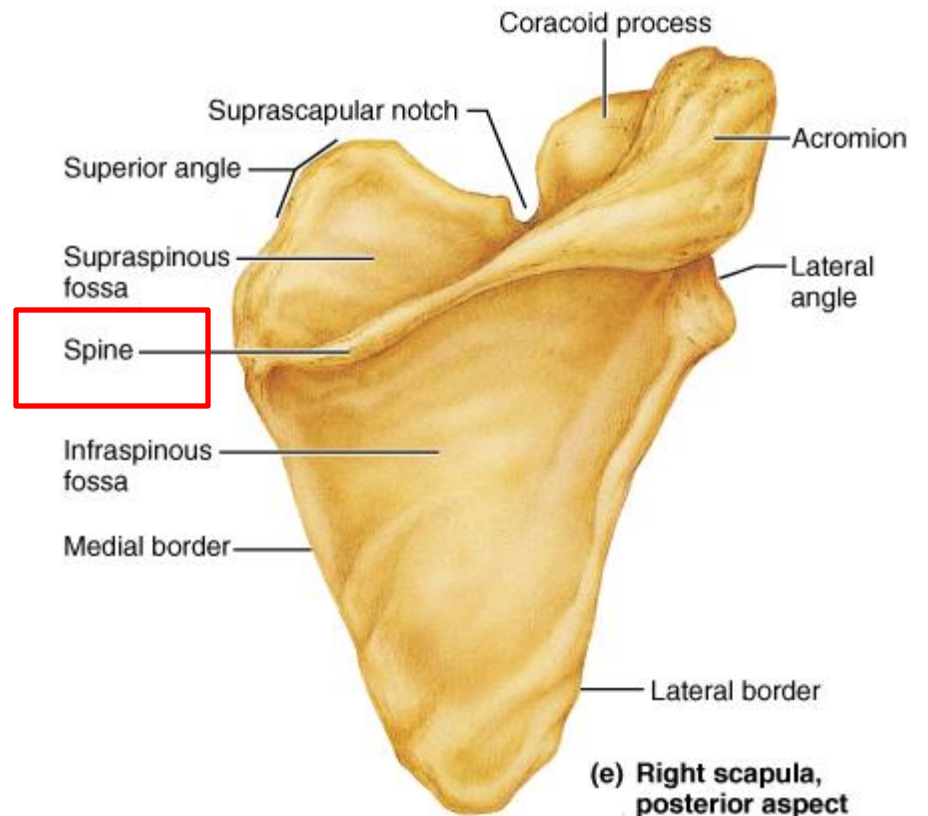






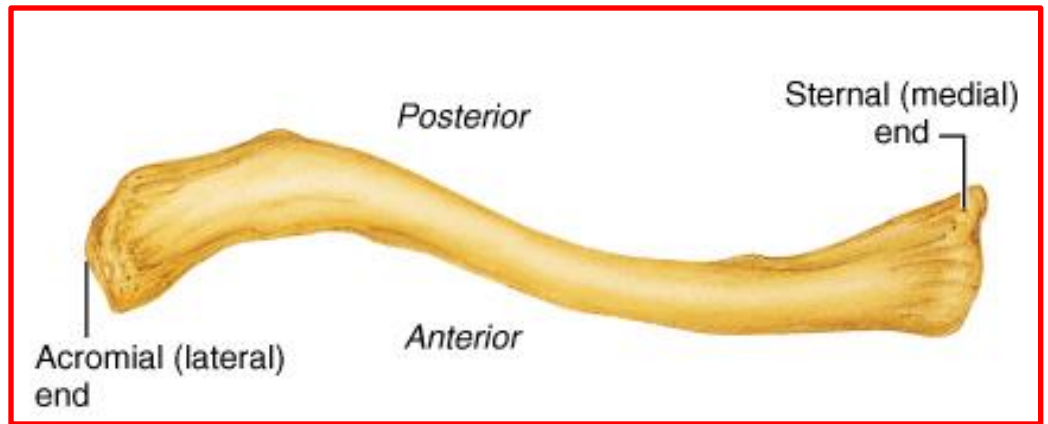


(d) Right scapula, anterior aspect

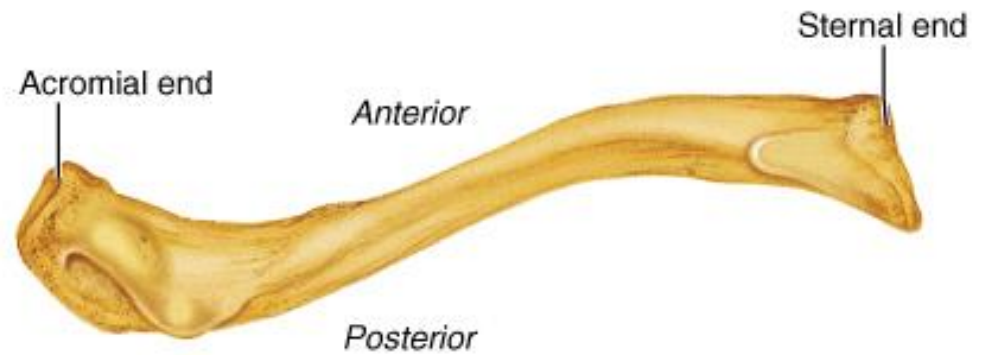


(e) Right scapula, posterior aspect



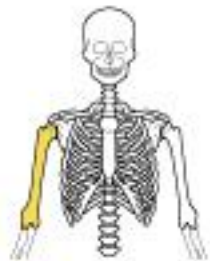
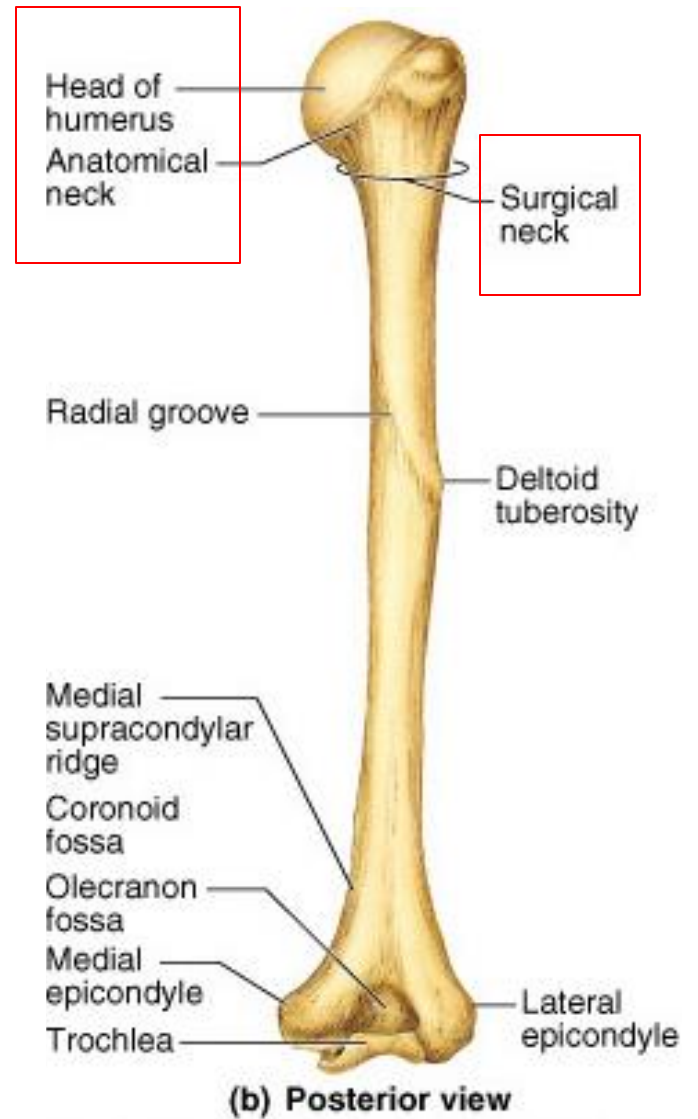
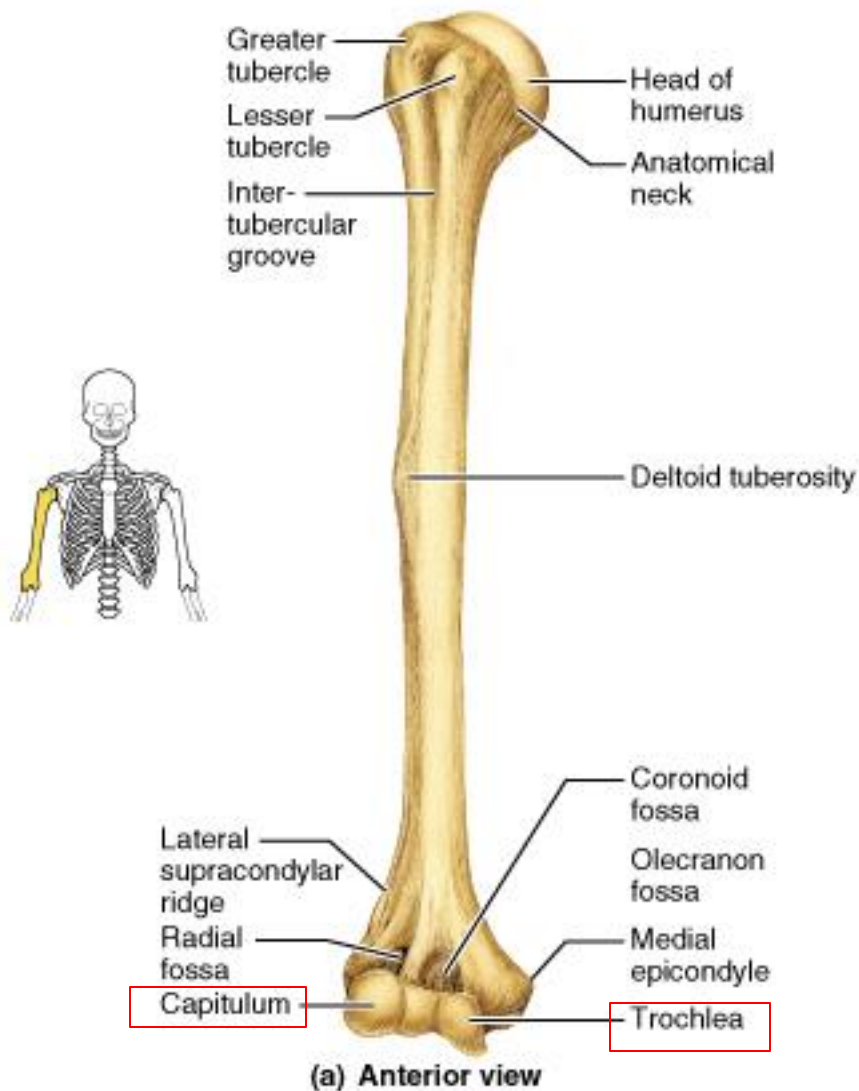


**(b) Right clavicle, superior view**

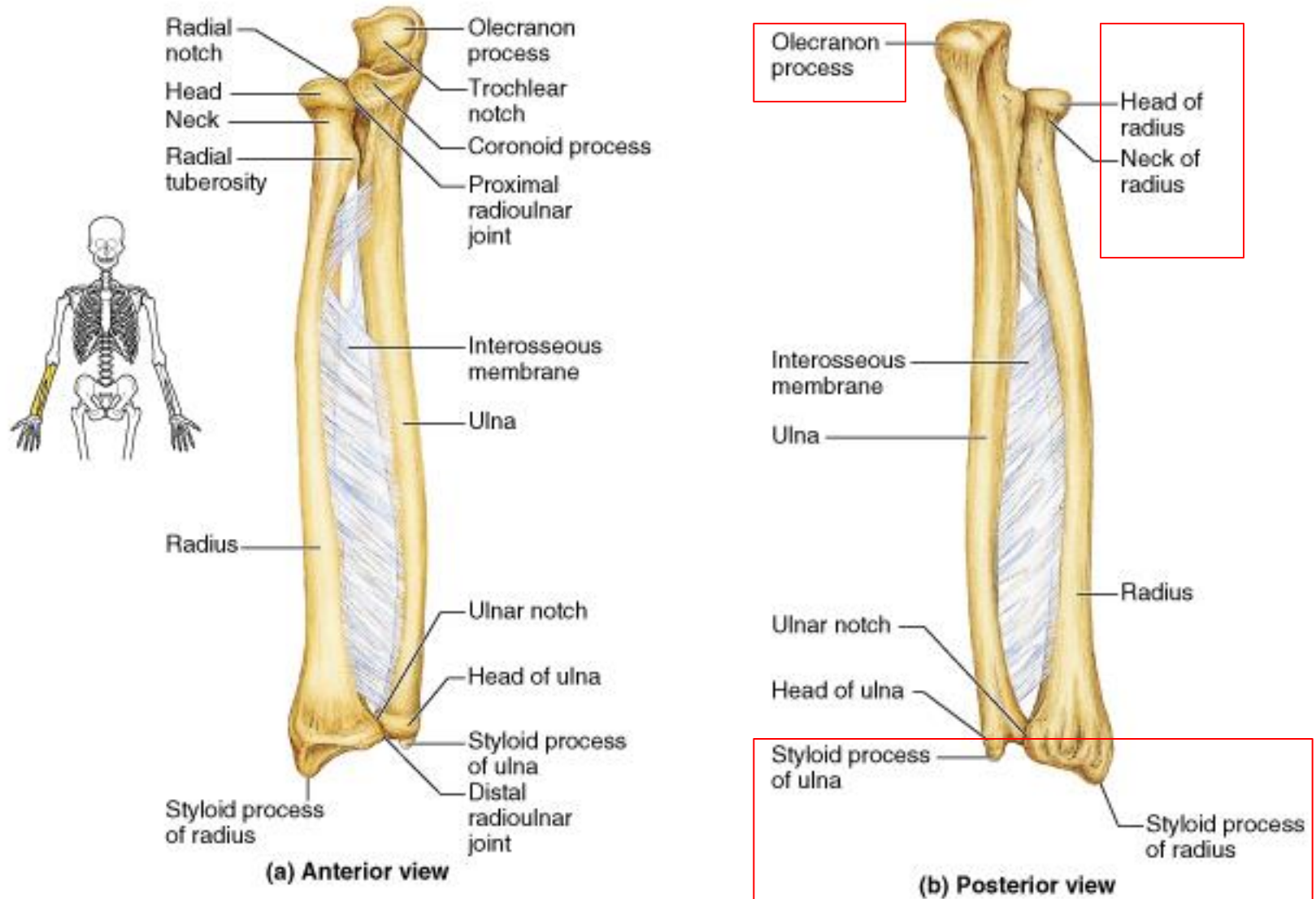


**(c) Right clavicle, inferior view**

# HUMEROUS



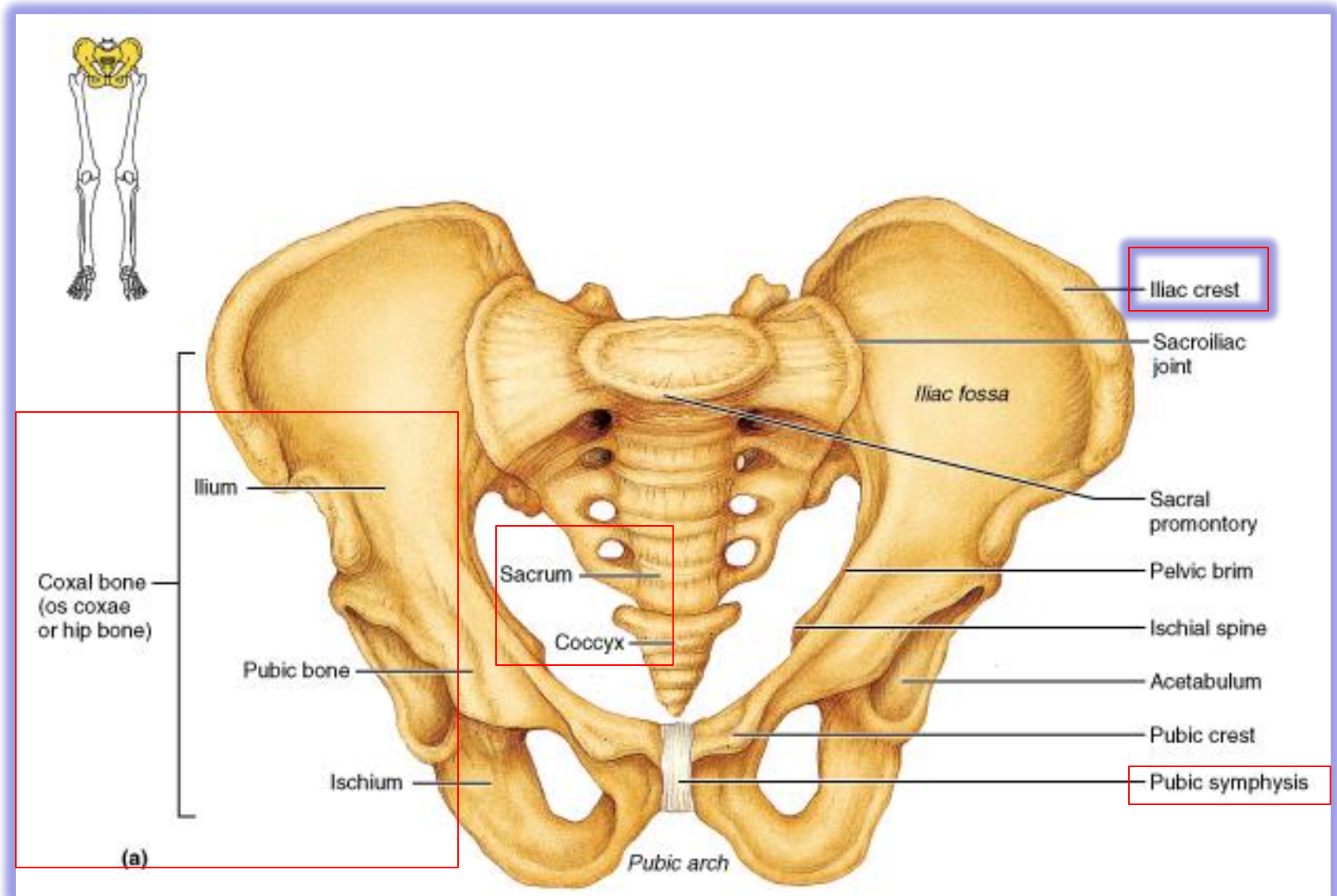
# Forearm



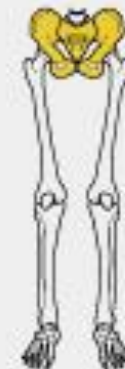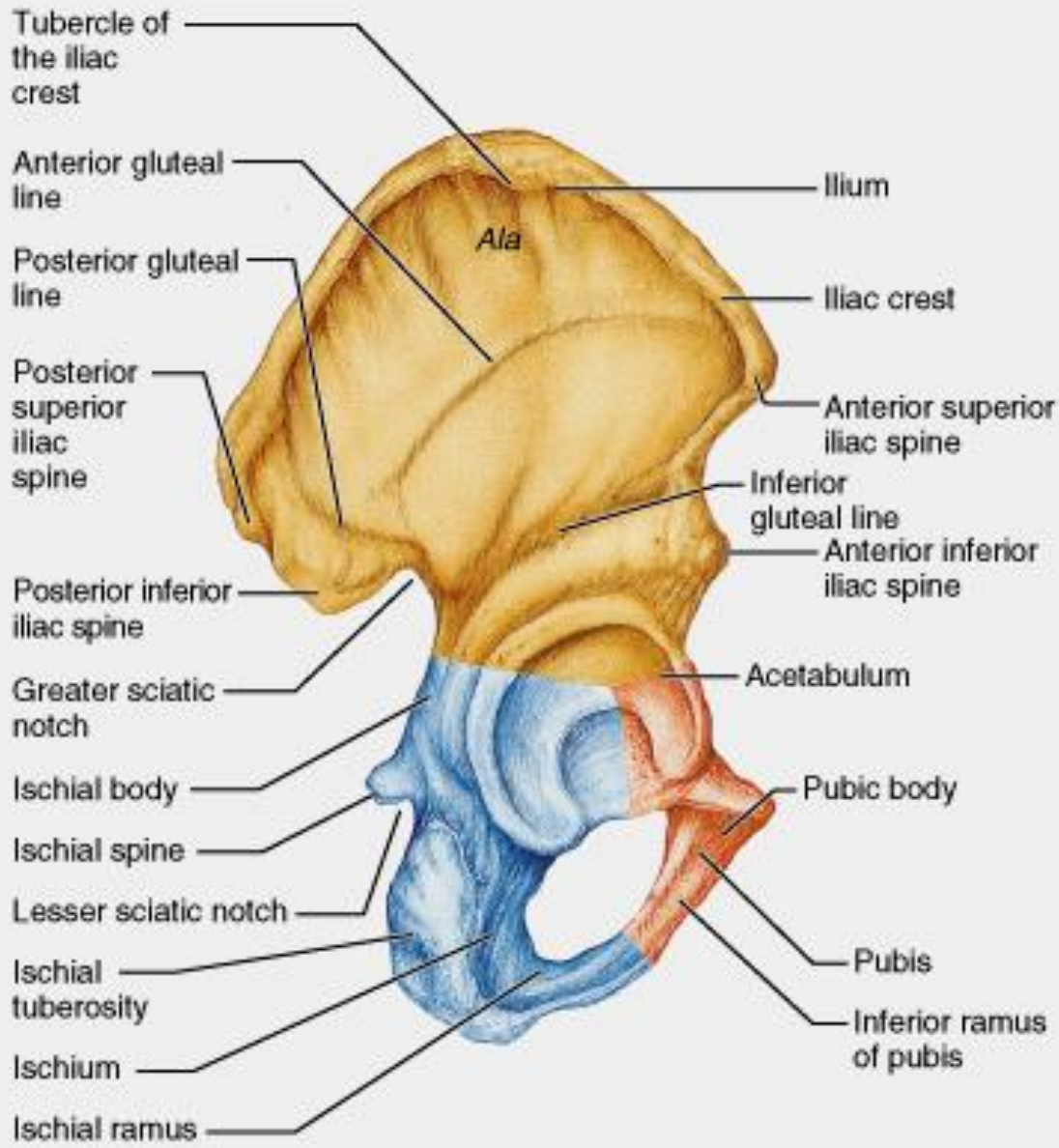




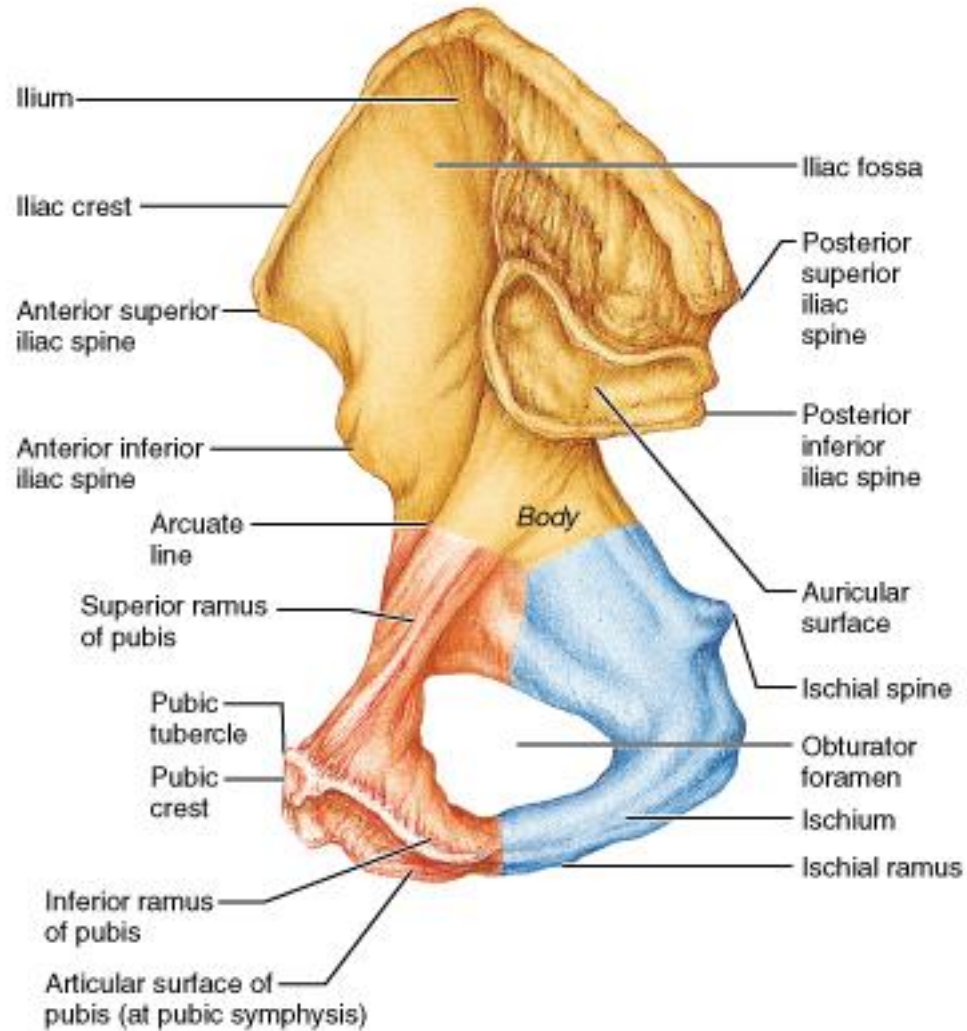
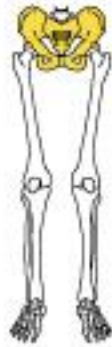# Pelvic Girdle (Hip)



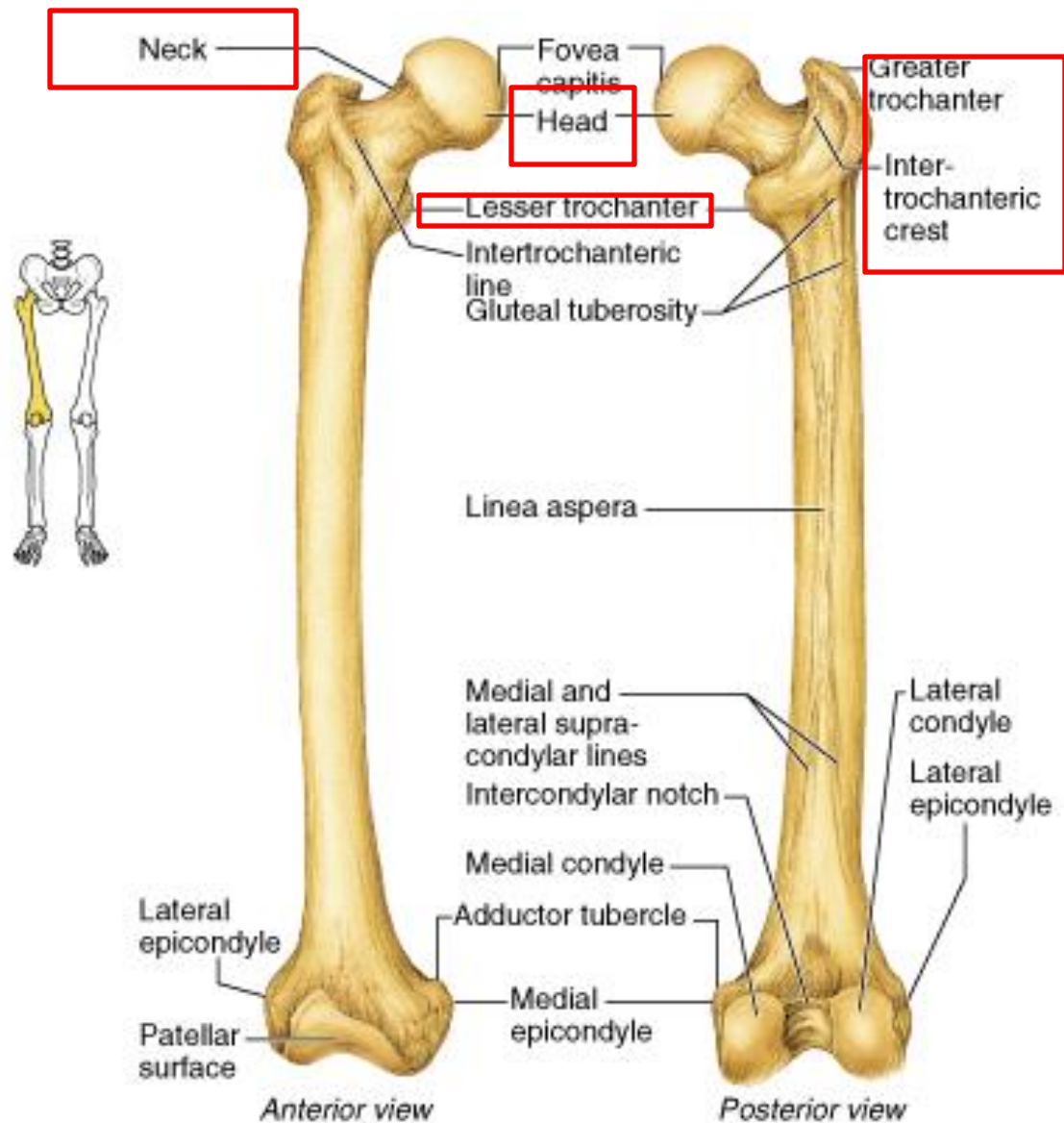
# Ilium



# Ilium



(c)



**(b) Femur**



# Tibia

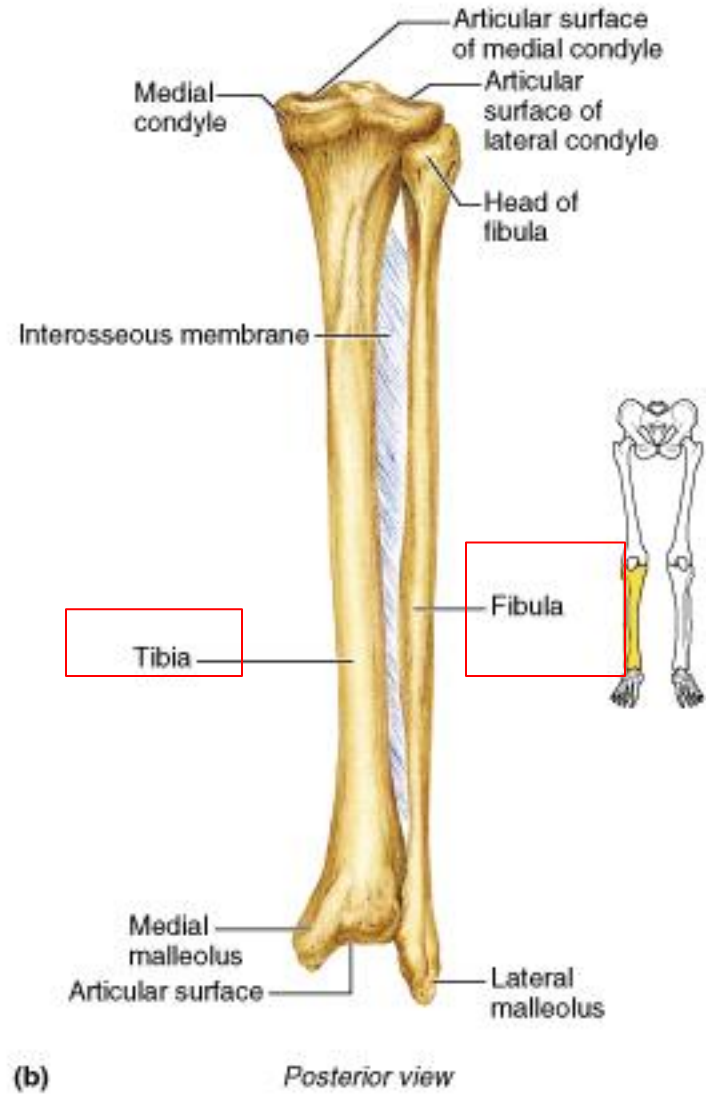
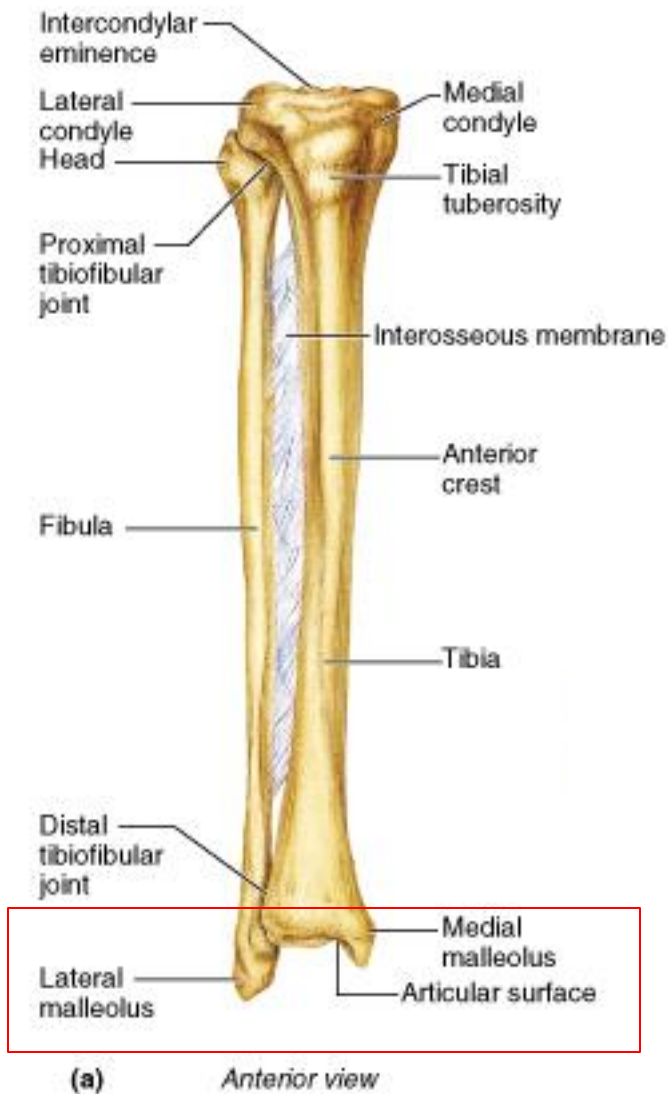


Figure 7.29a, b

# Bony Thorax (Thoracic Cage)

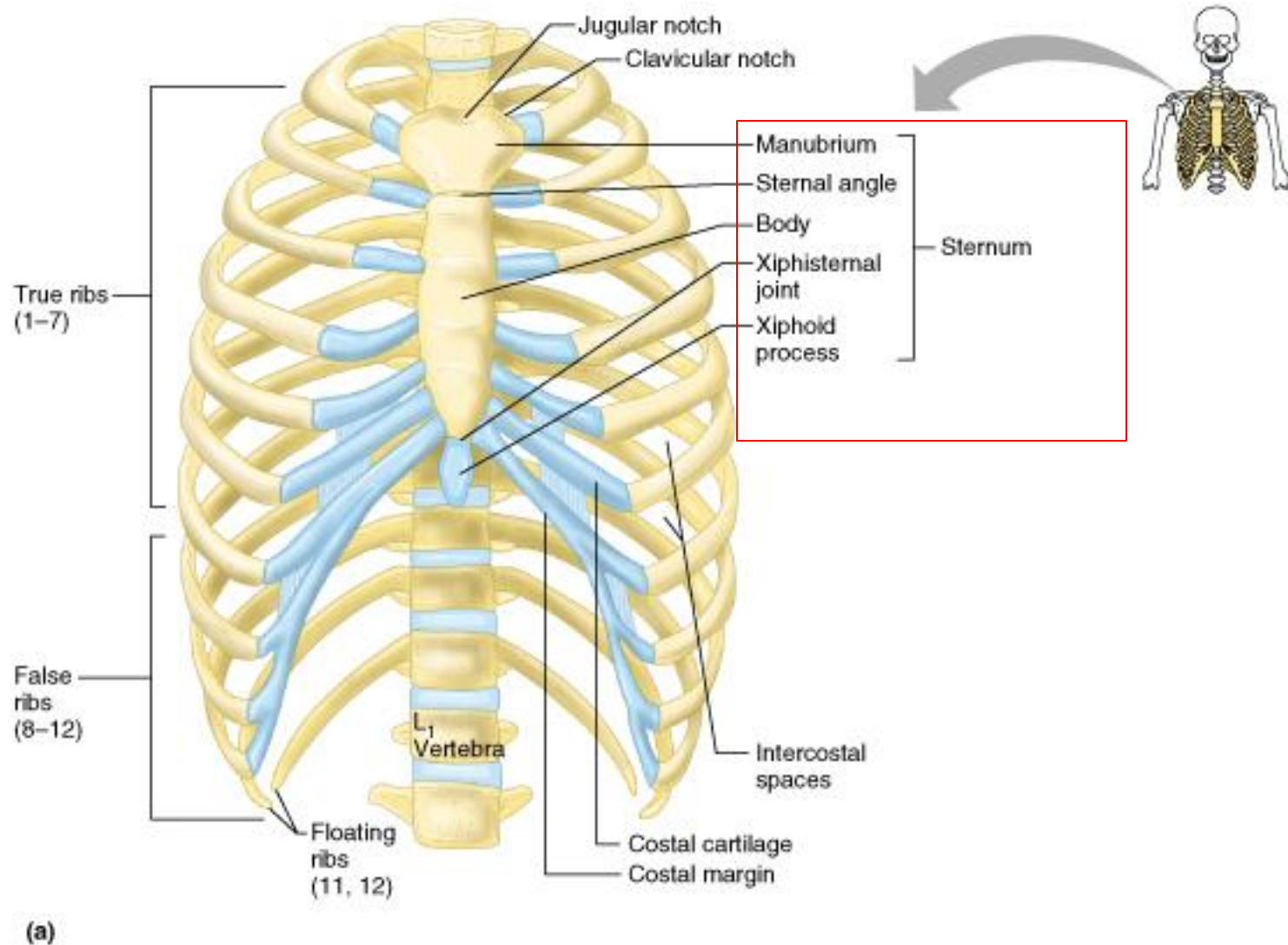
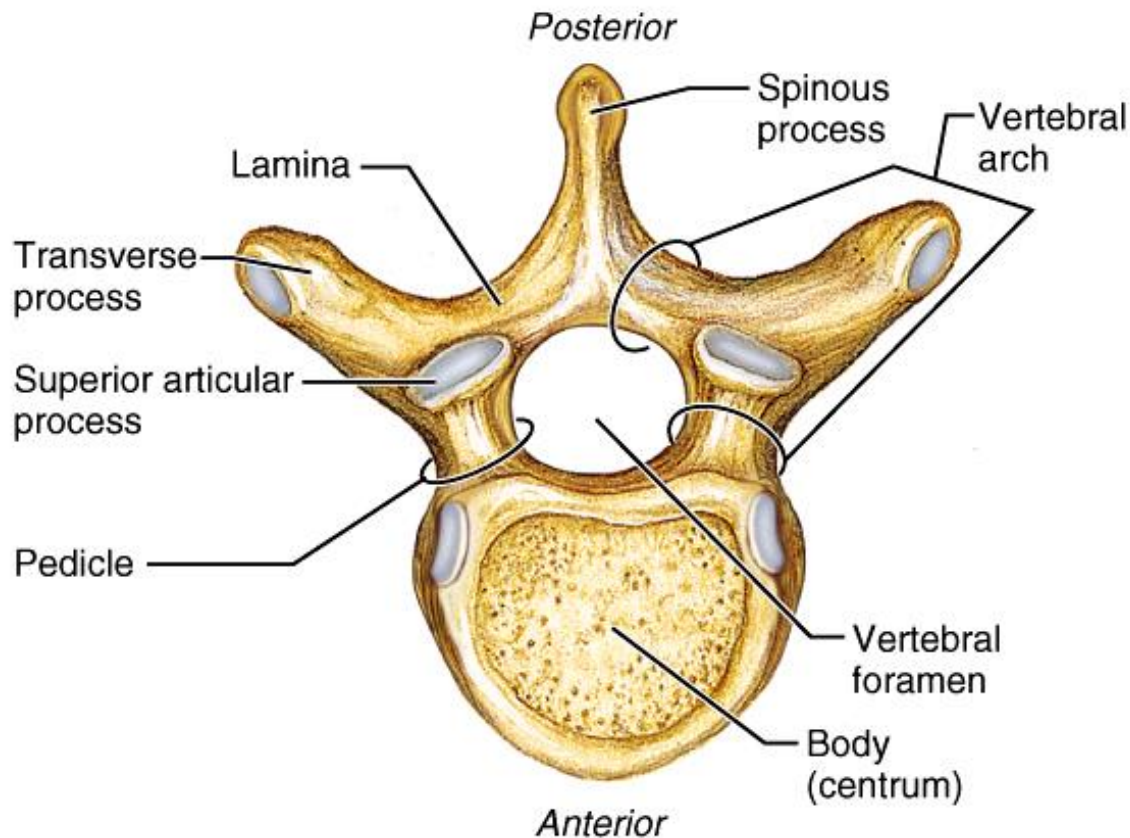
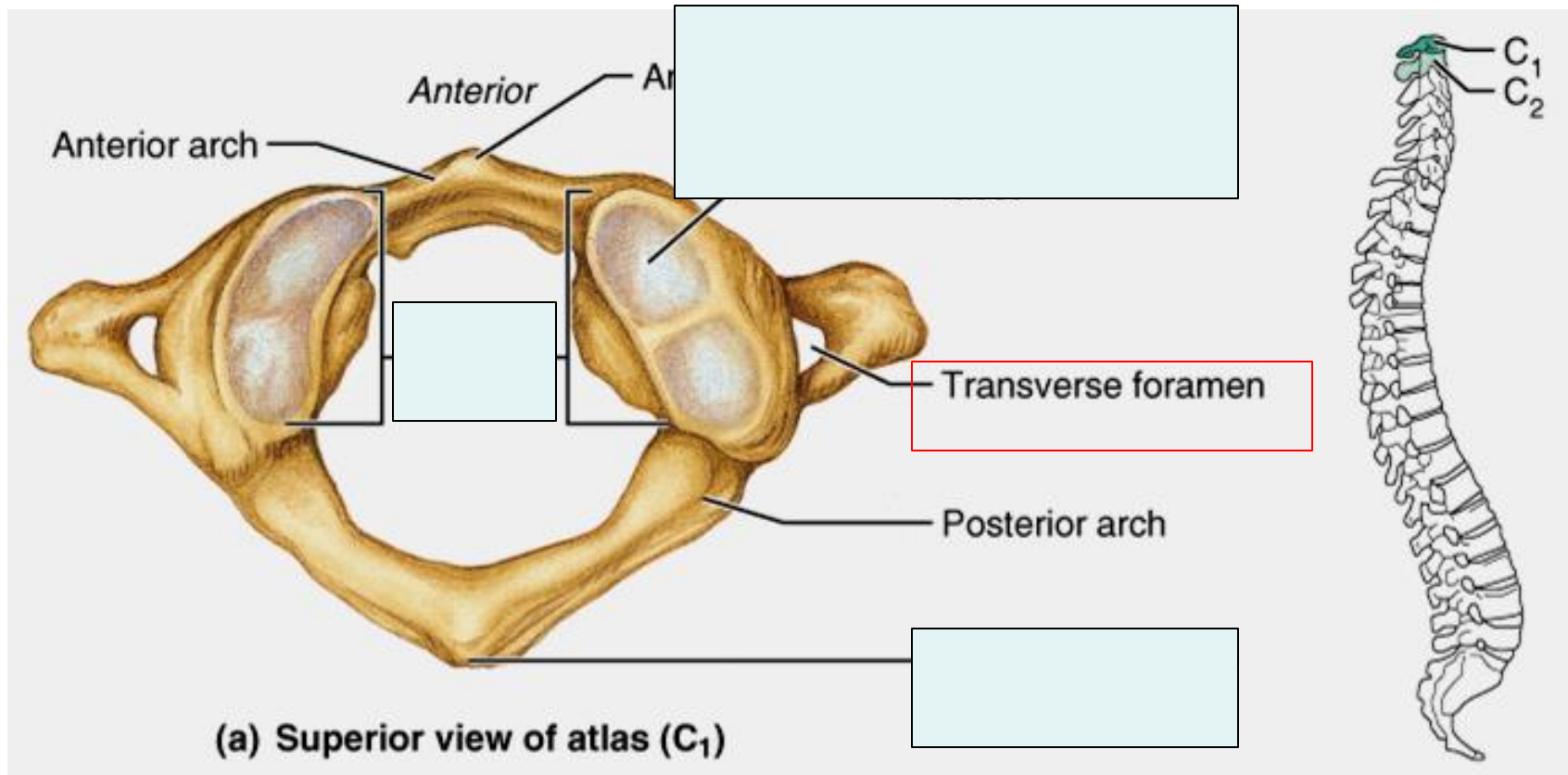


Figure 7.19a

# General Structure of Typical Vertebrae



# Cervical Vertebrae: Atlas (C<sub>1</sub>)



# Thoracic Vertebrae

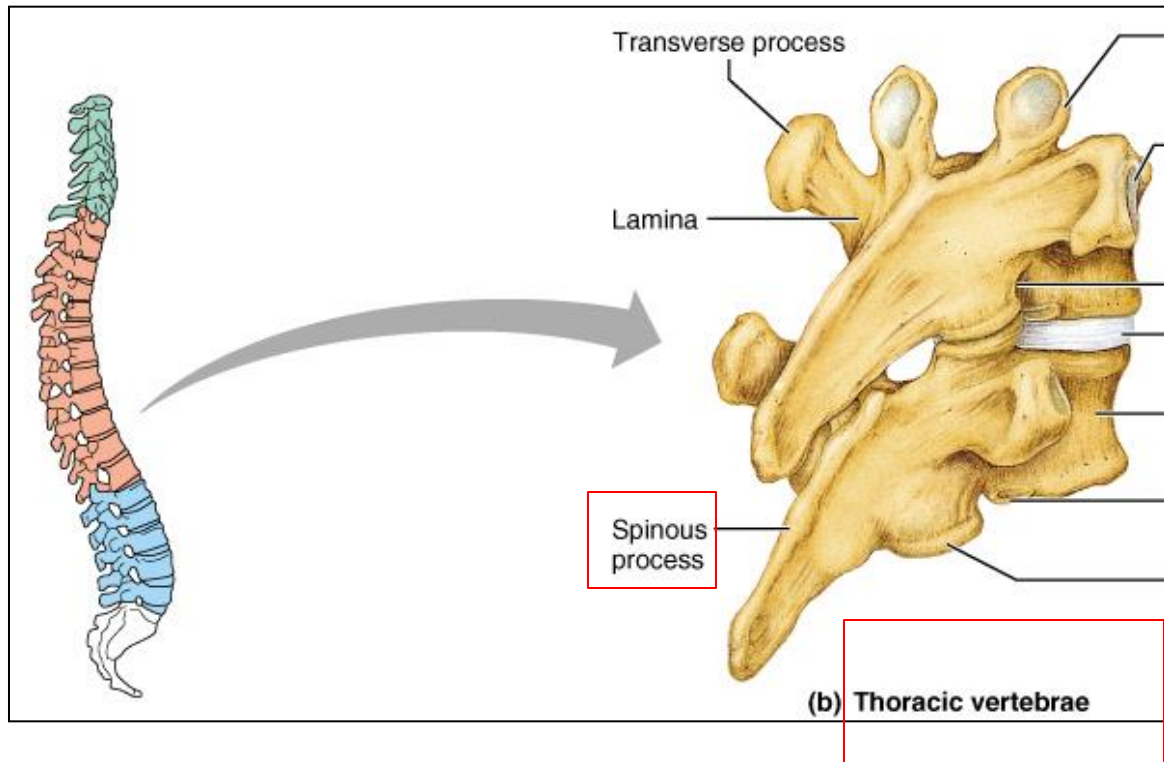


Figure 7.17b



# Lumbar Vertebrae

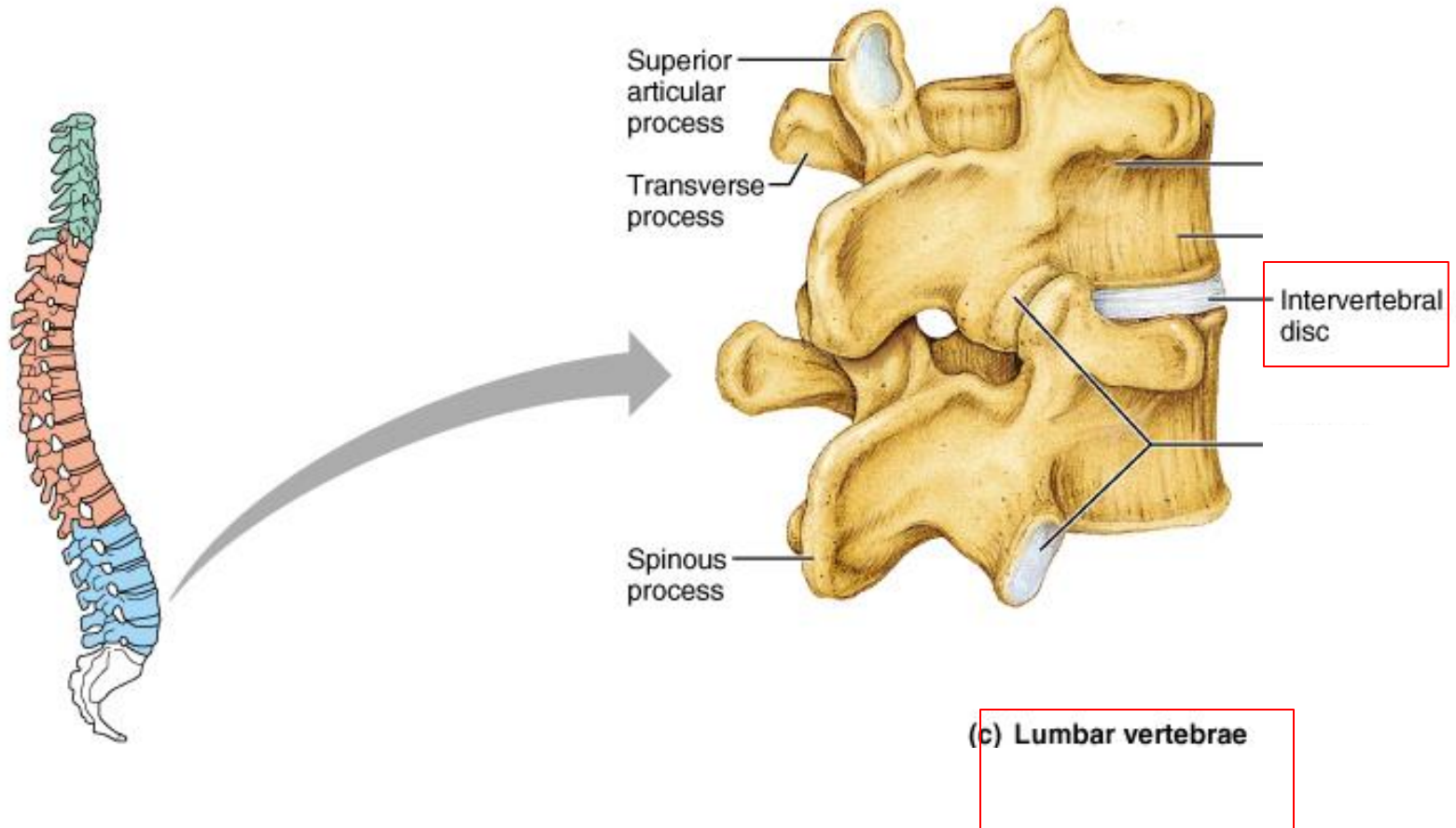
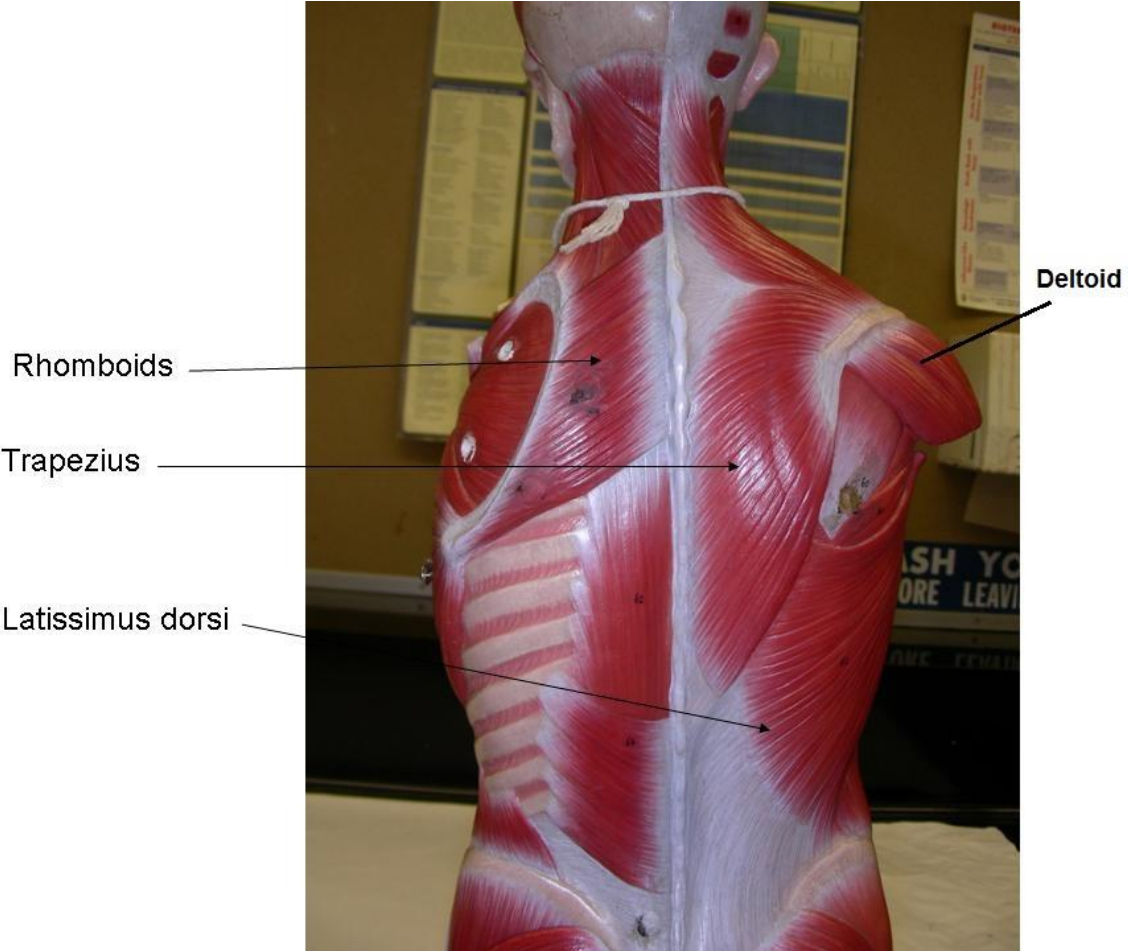
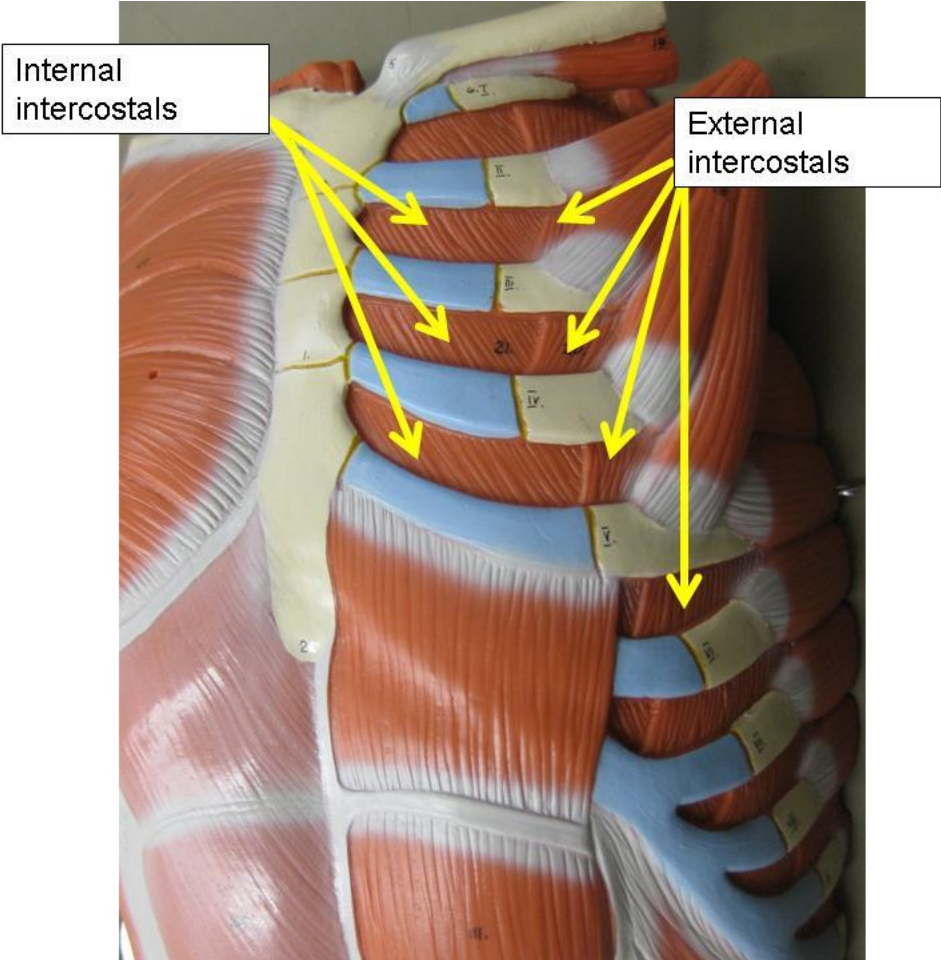


Figure 7.17c

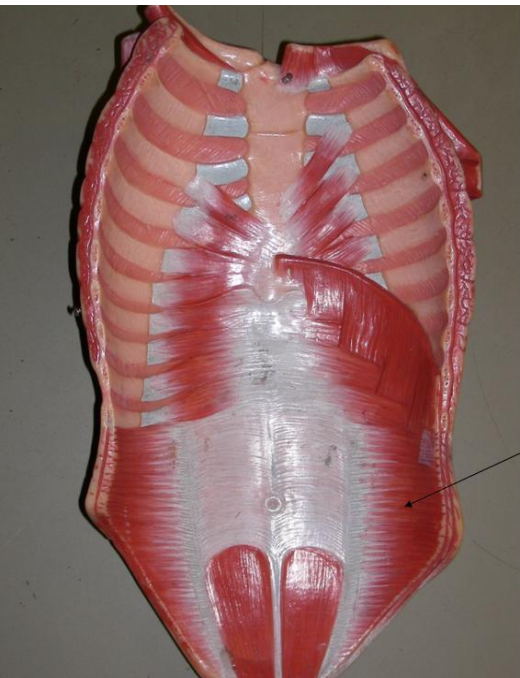# Muscle of the shoulder



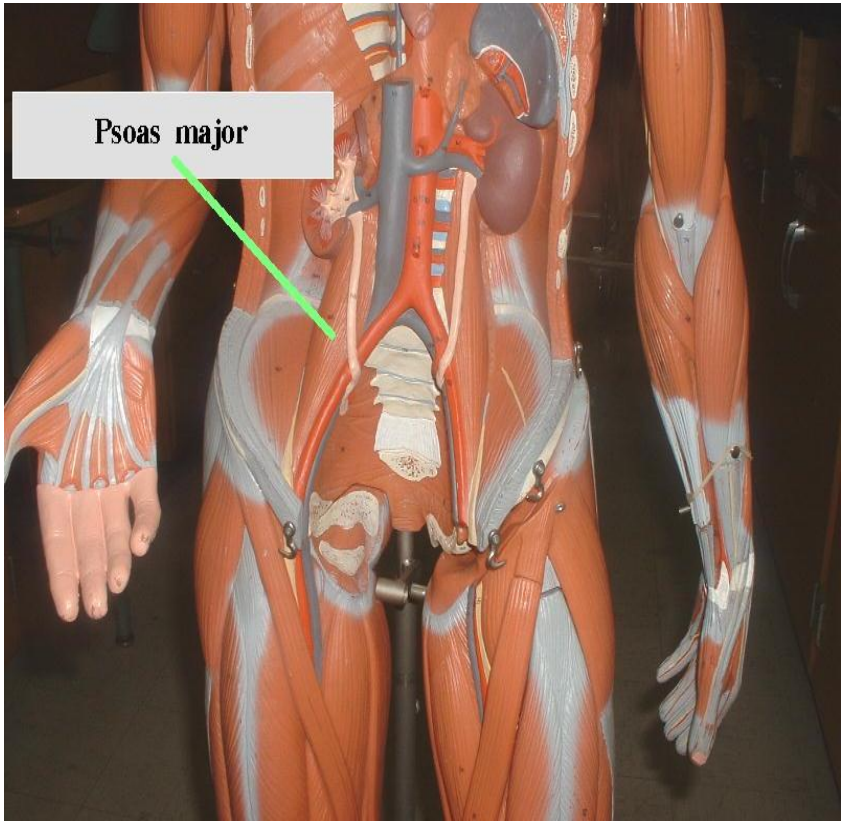
# Anterior view



# Muscles of the abdomen



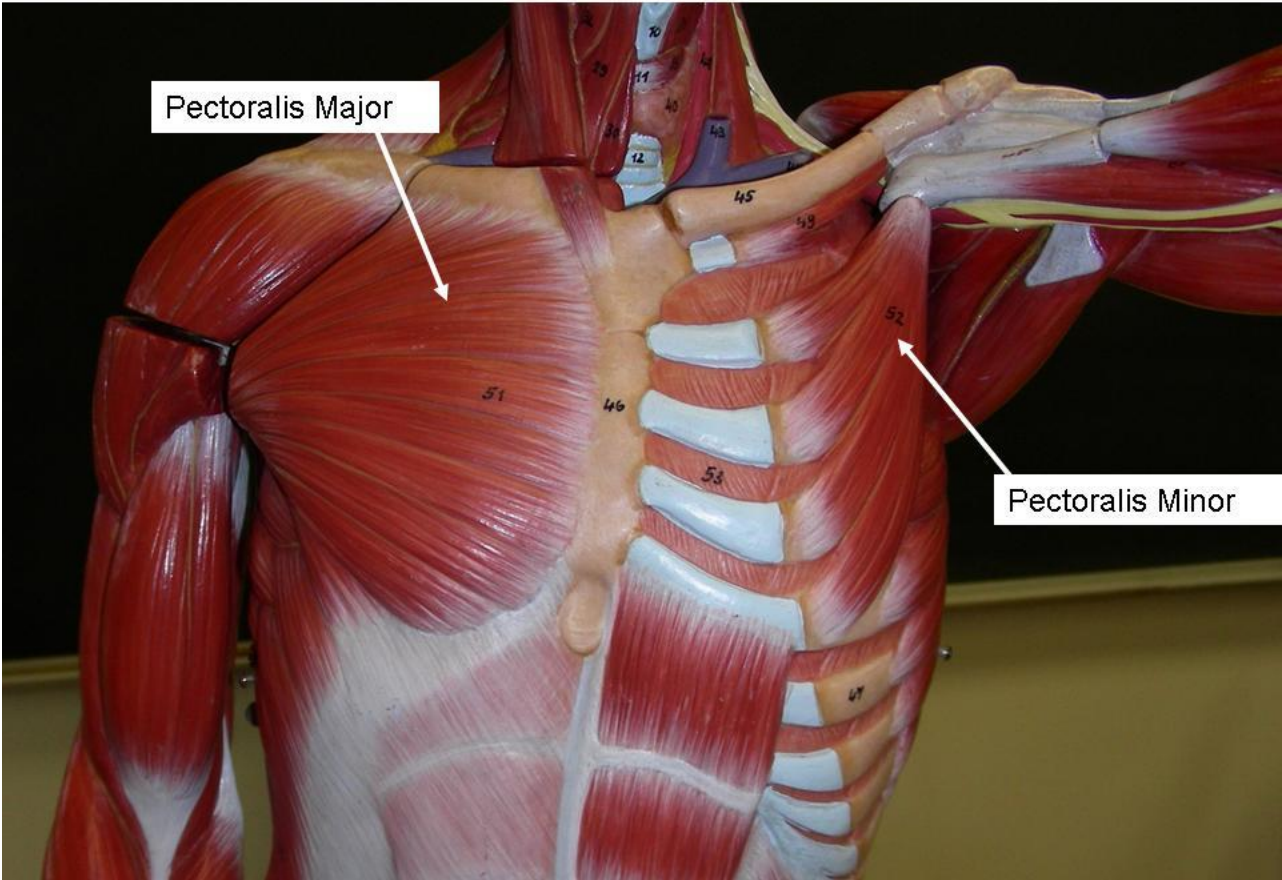
Transversus abdominis



Psoas major

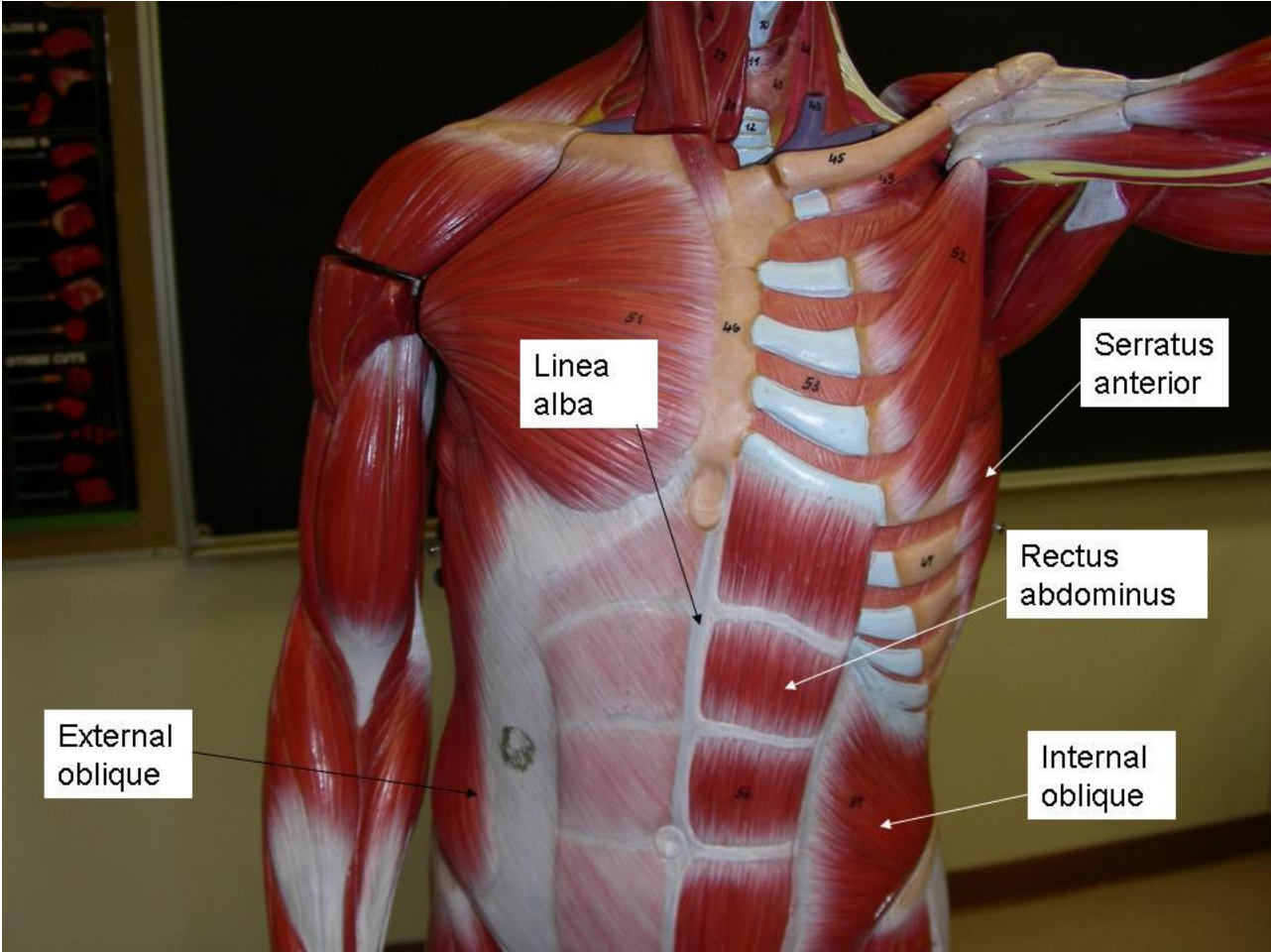


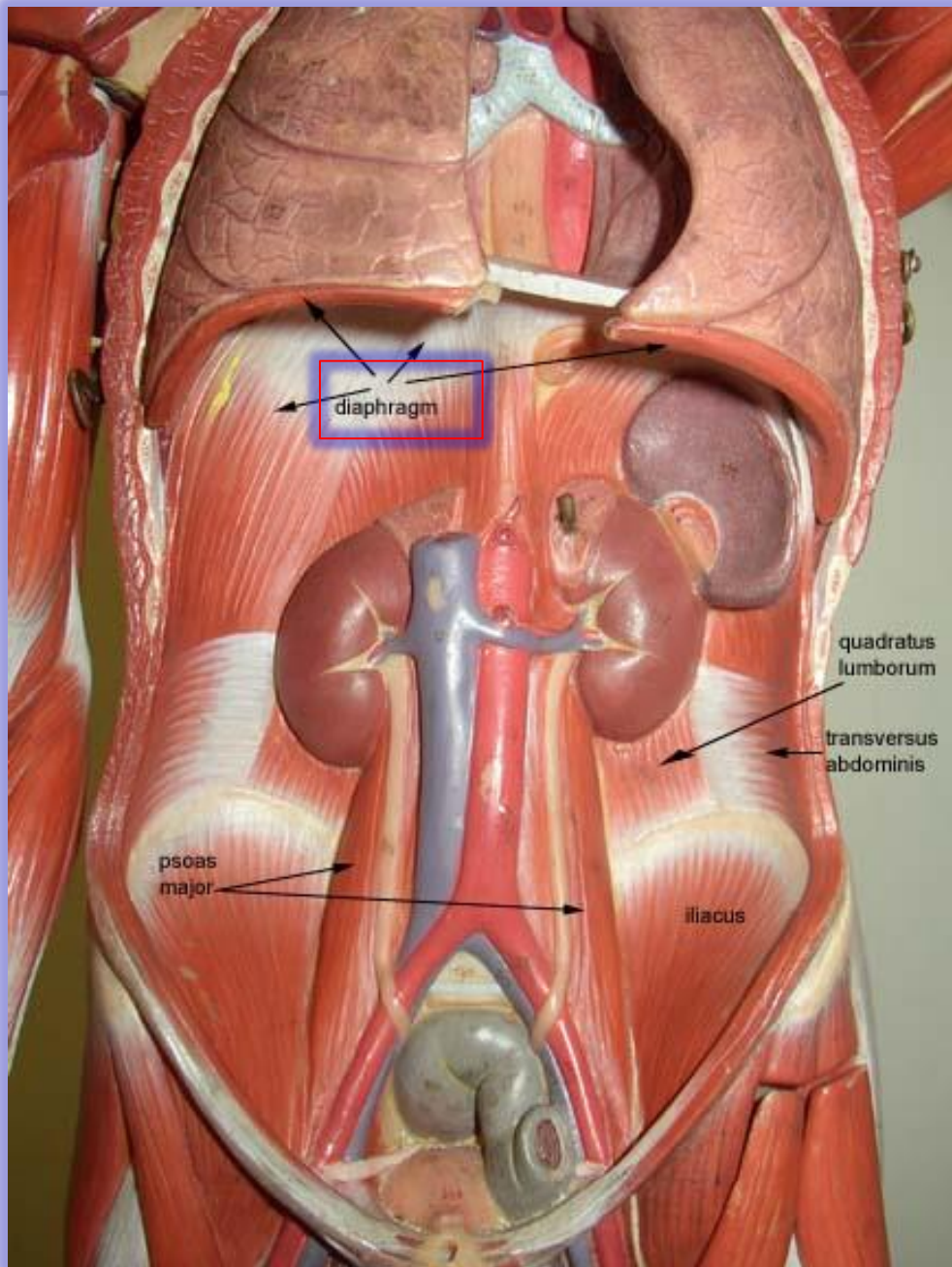
# Anterior view





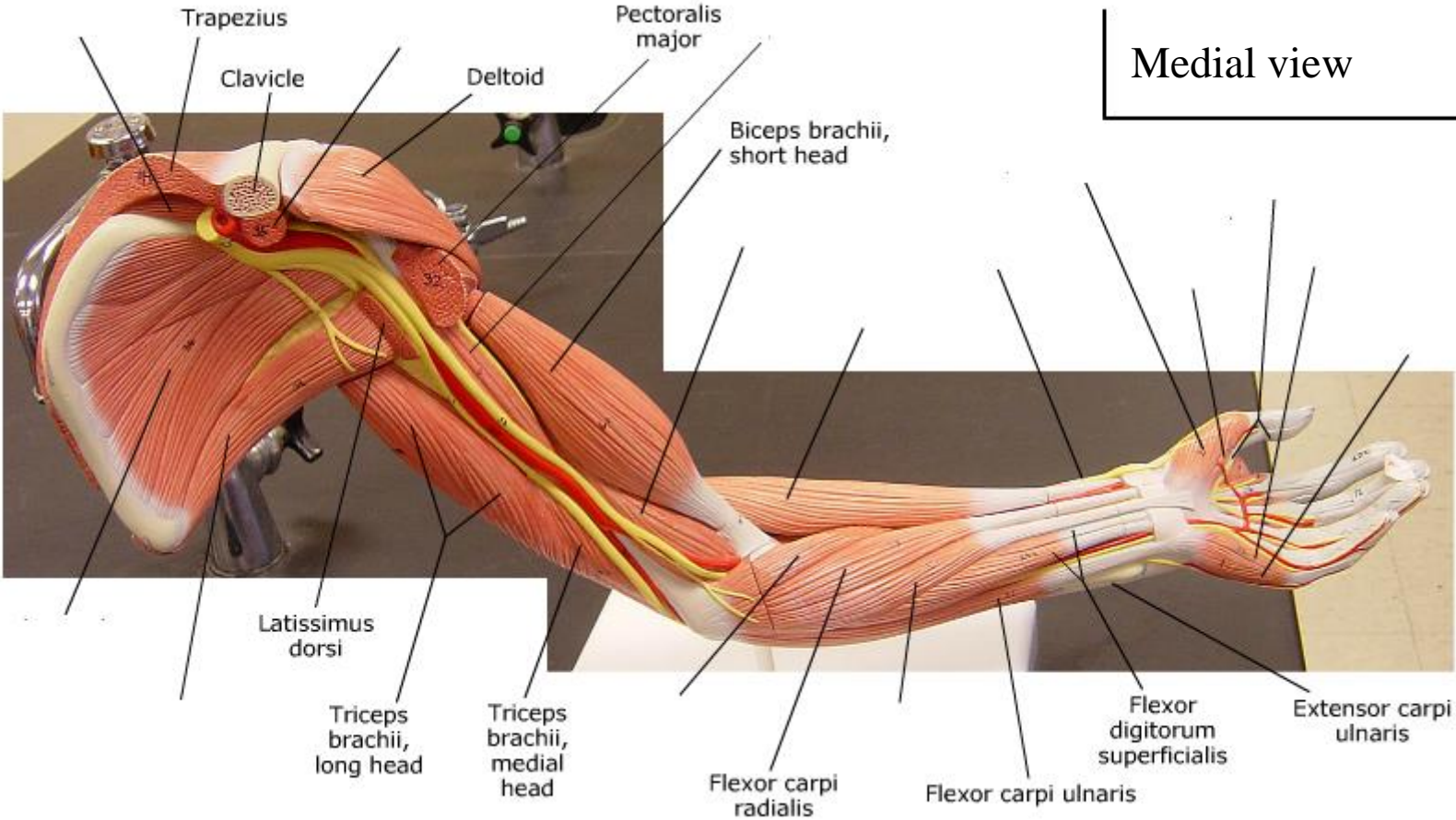
# Muscles of the abdomen



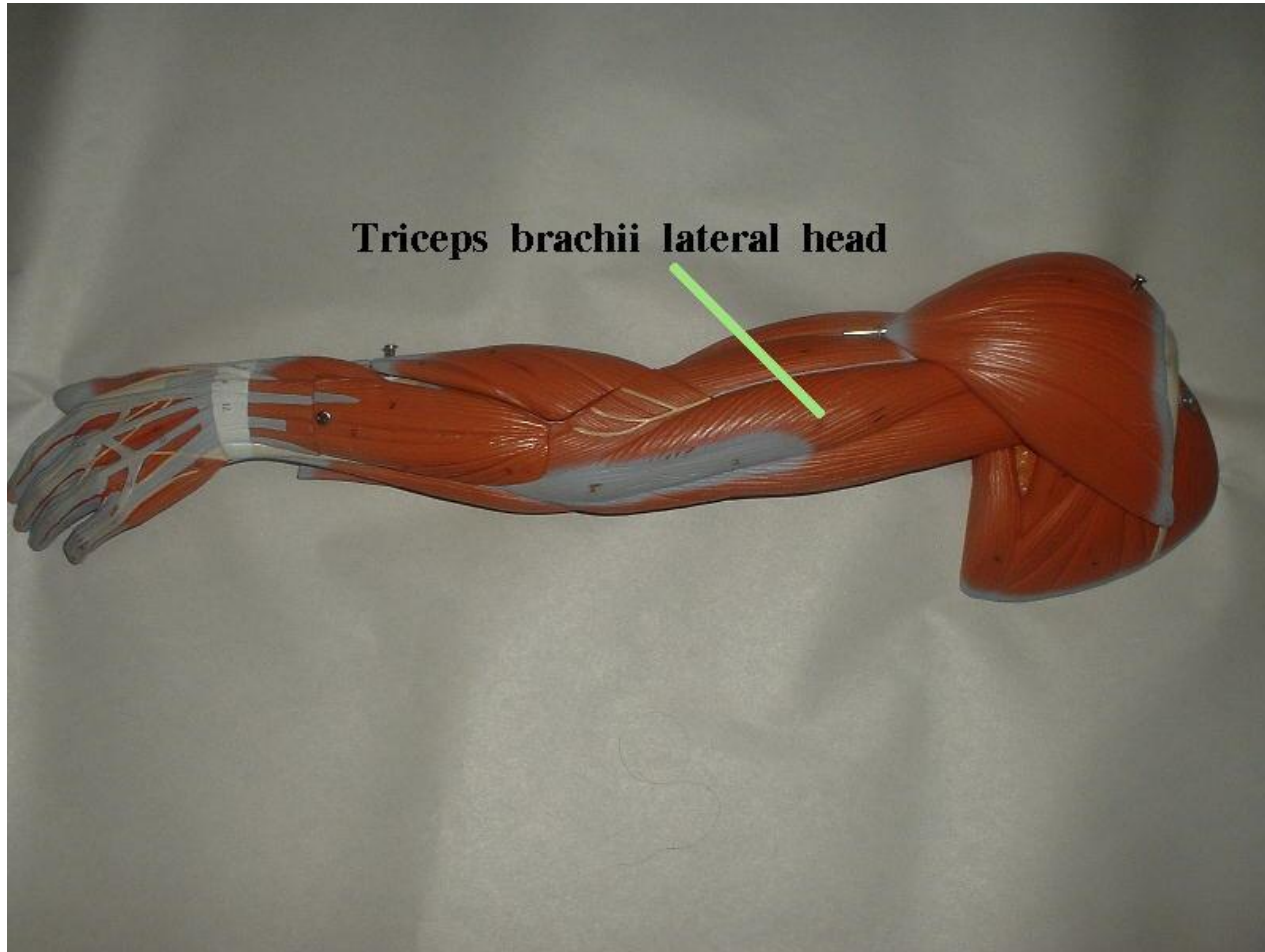


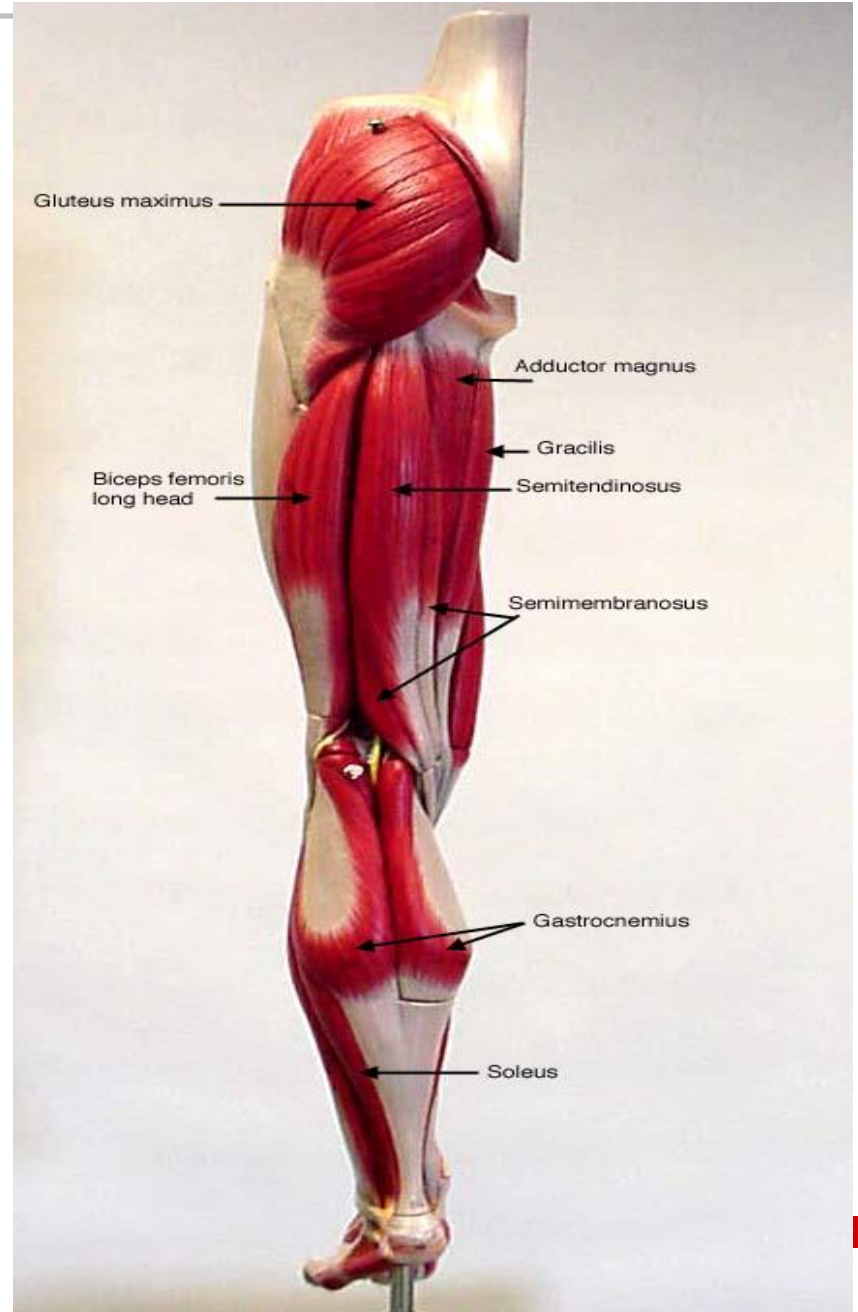
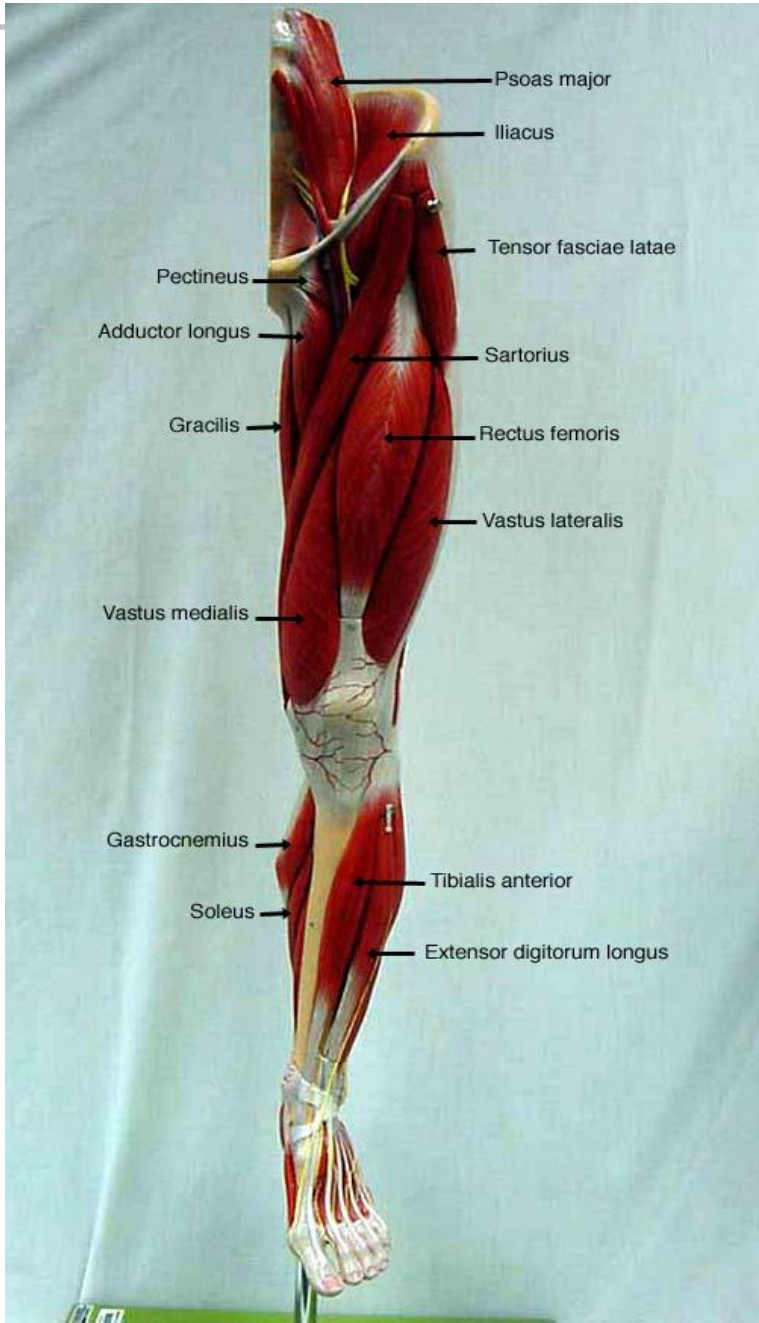
# Muscle of the Arm

Medial view

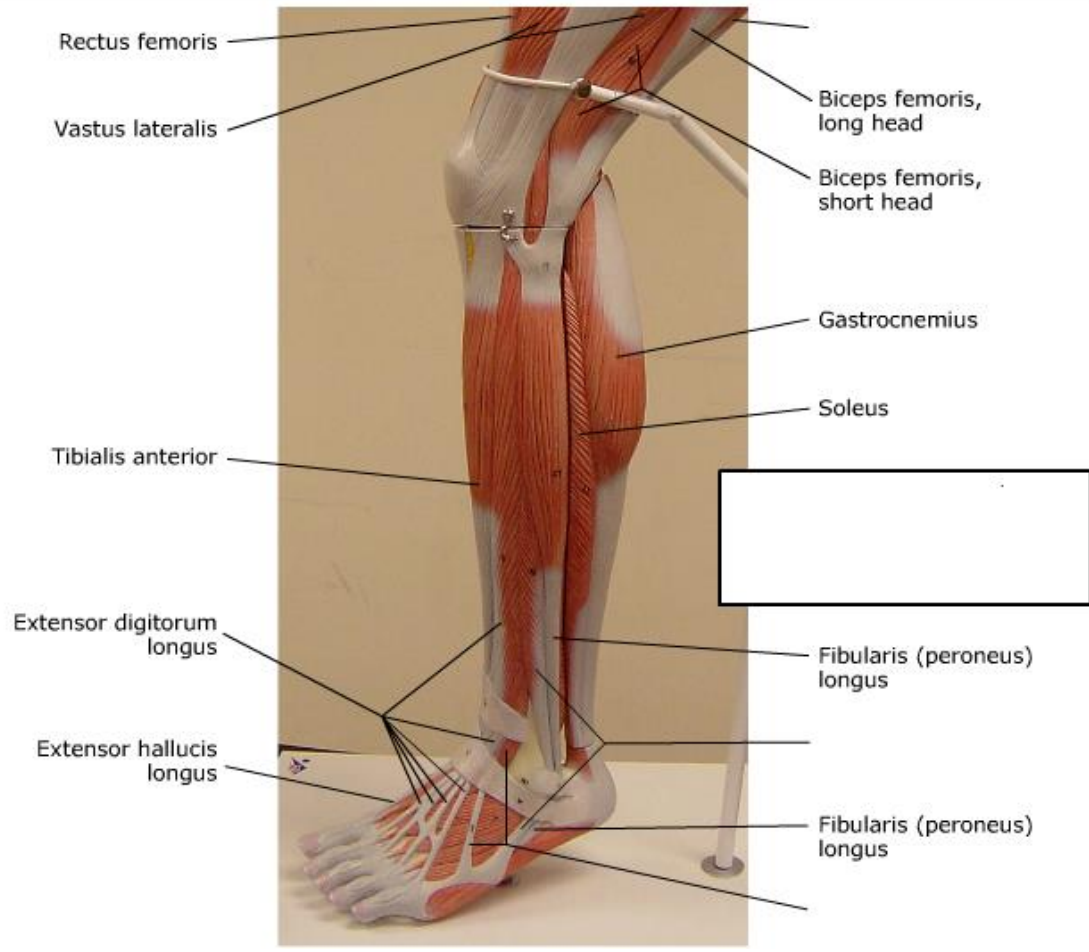


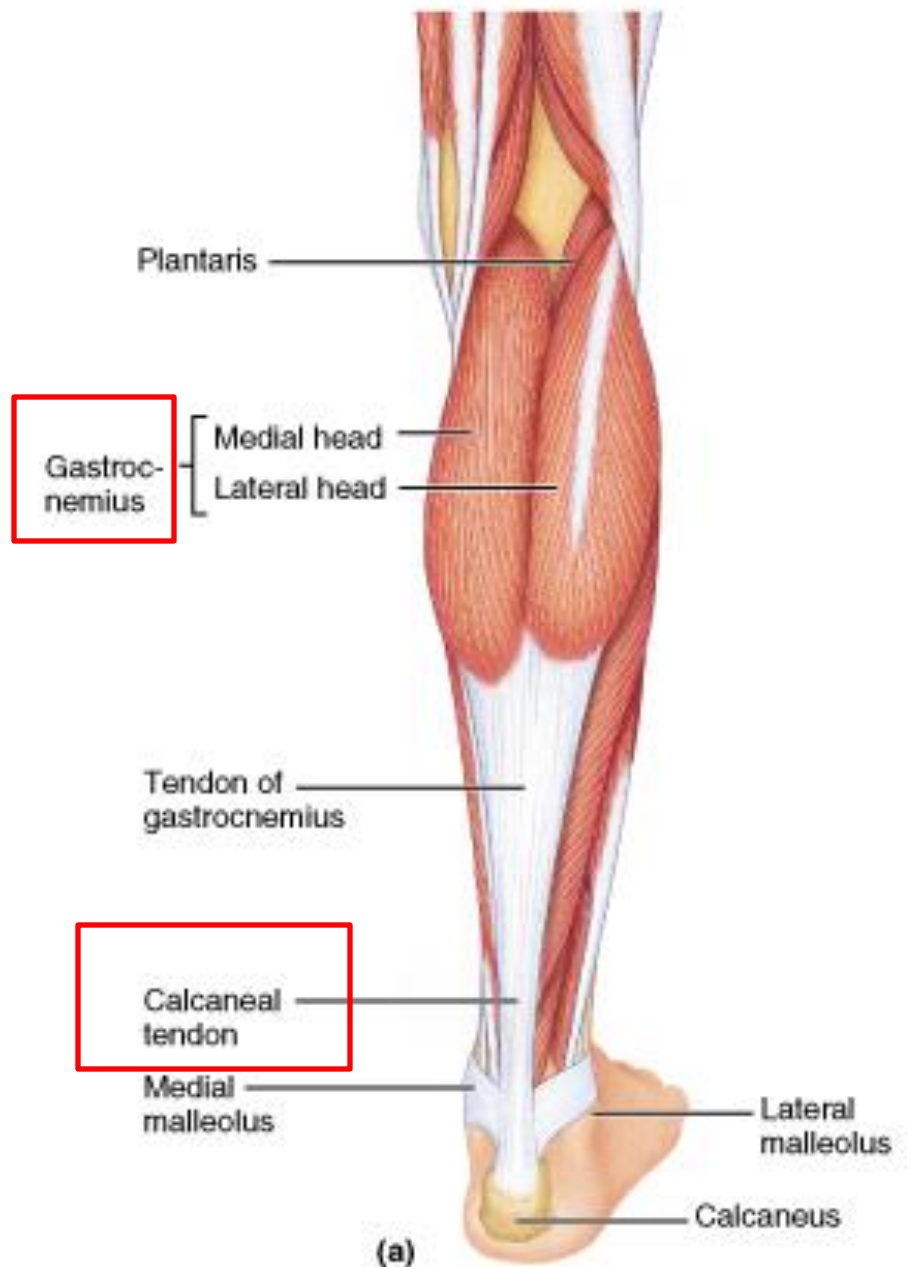


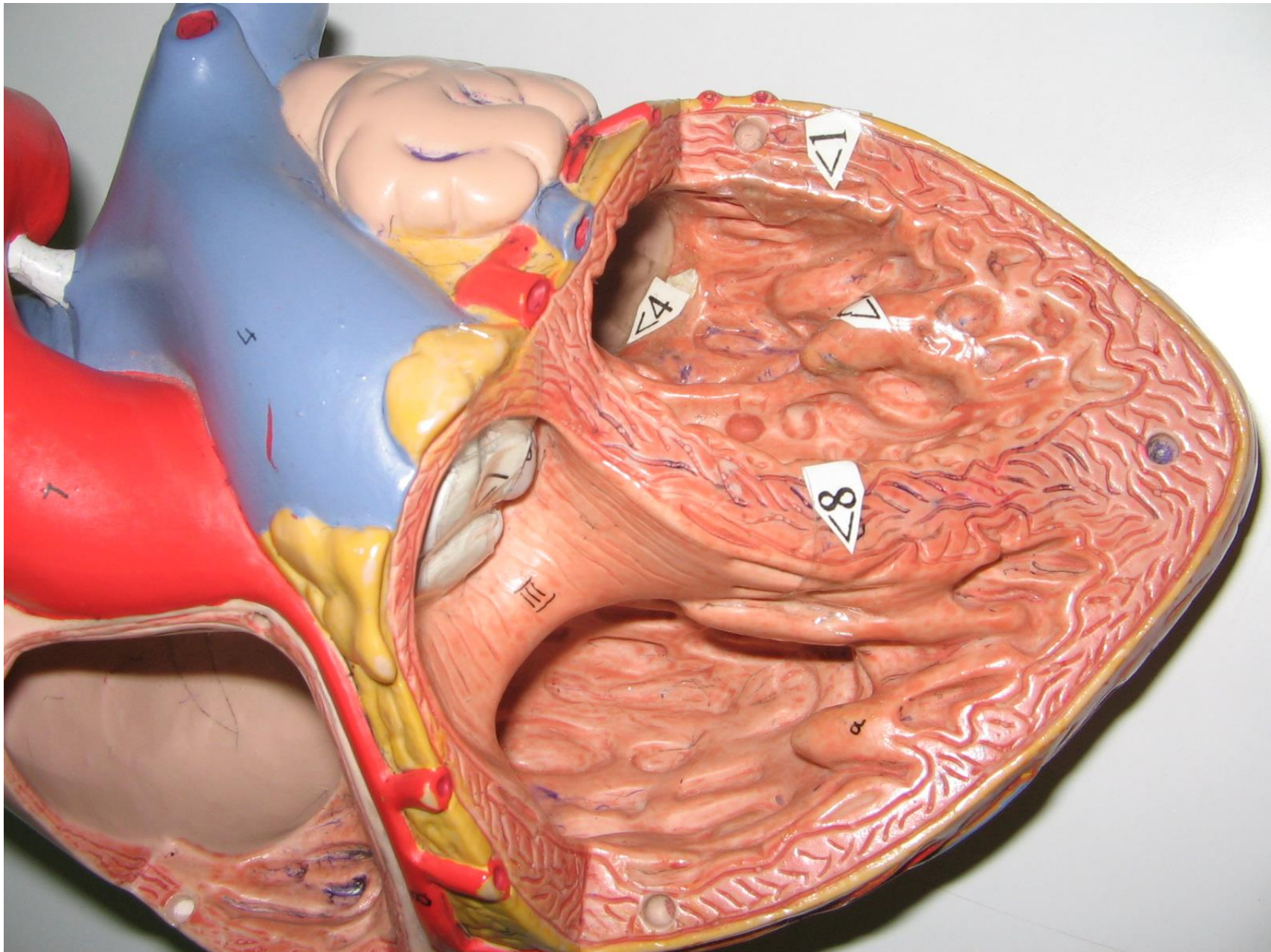




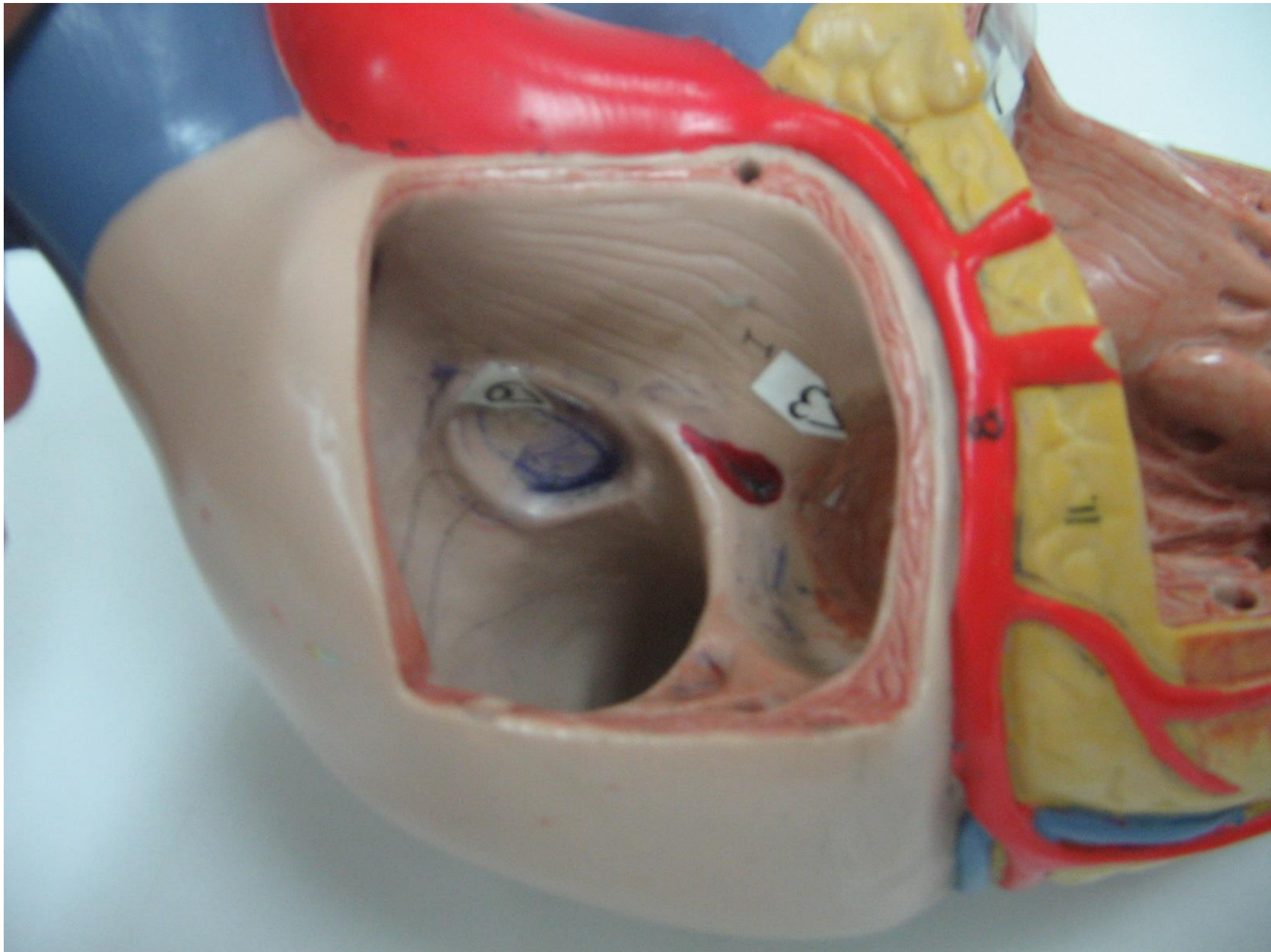


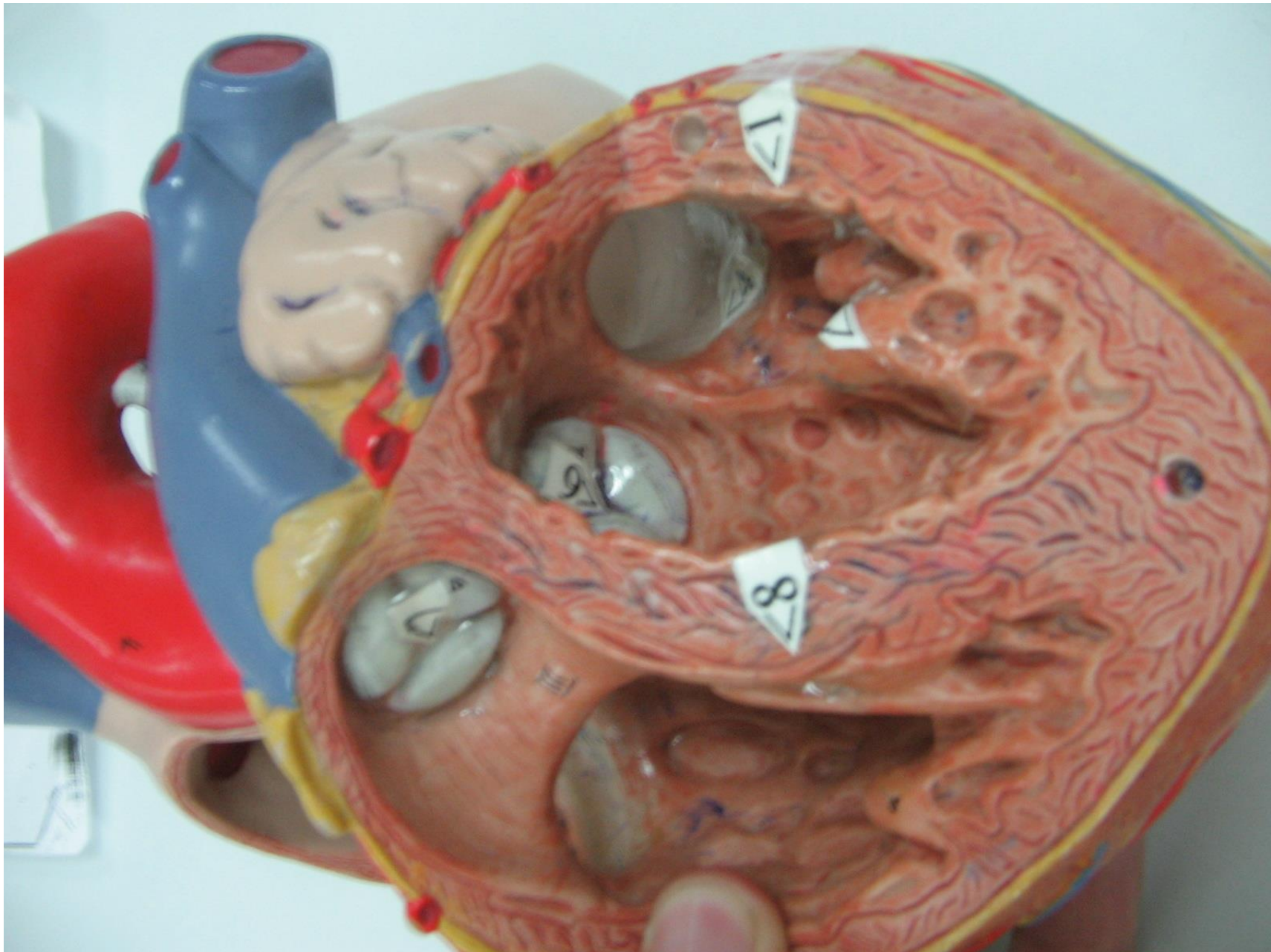






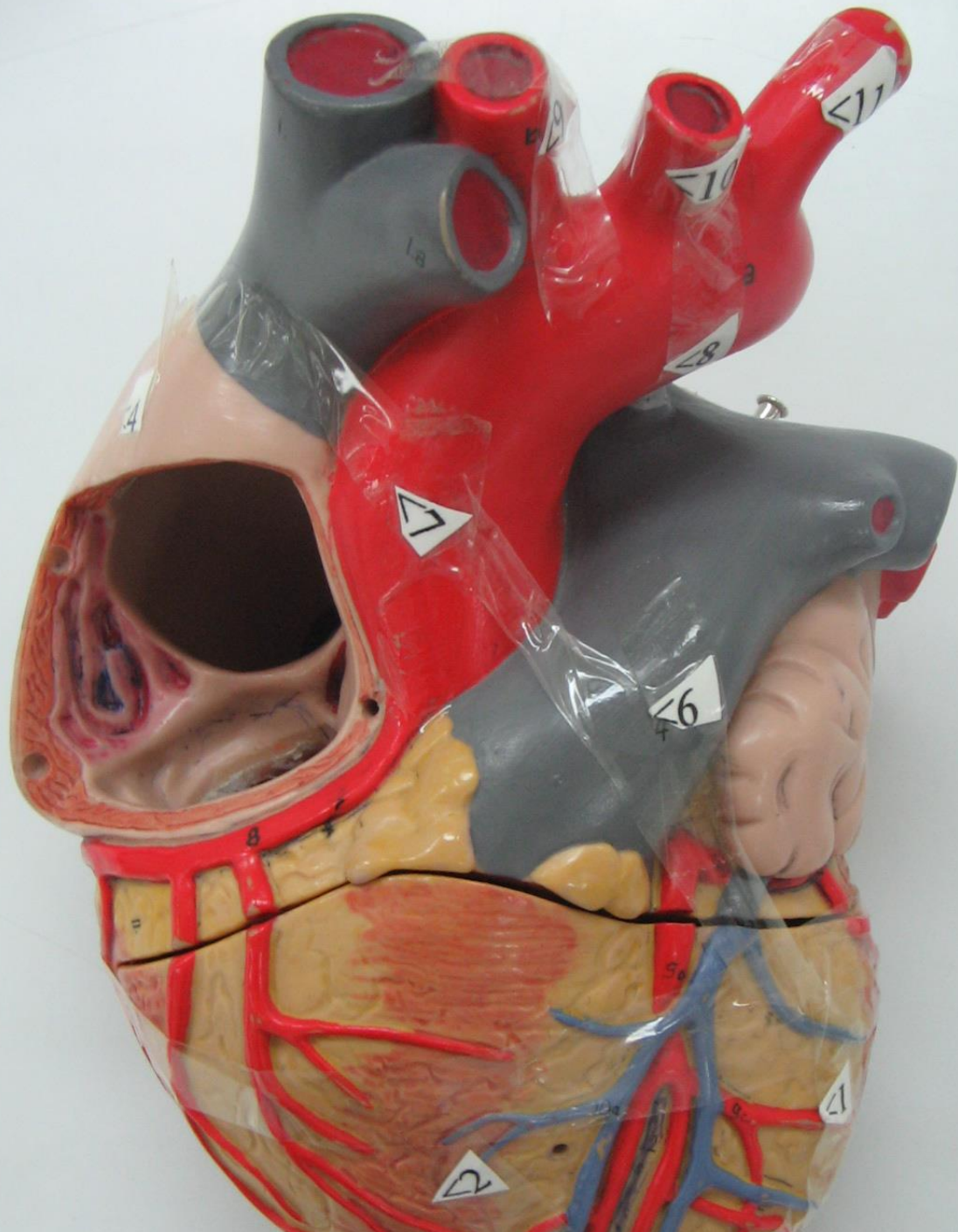




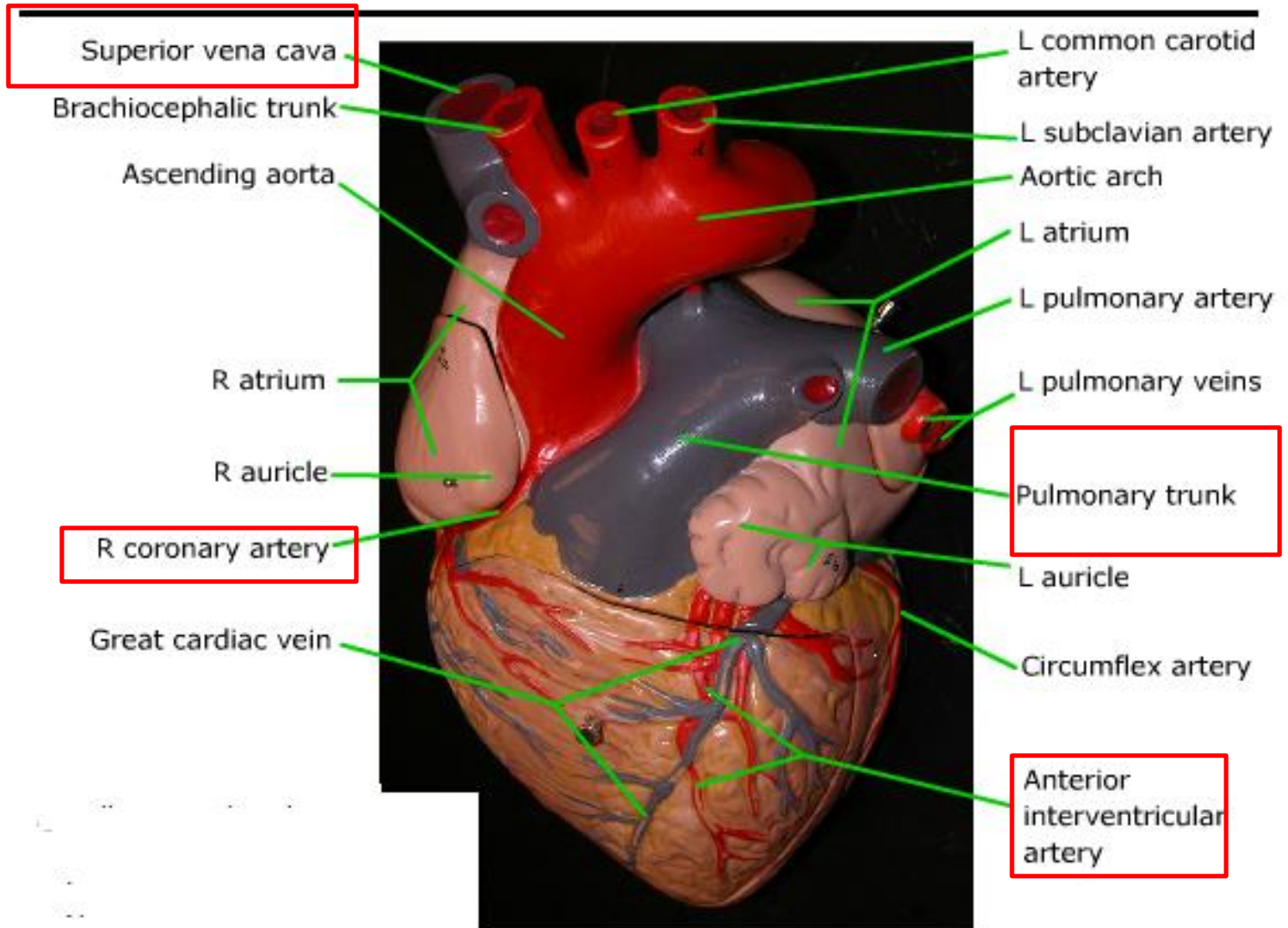




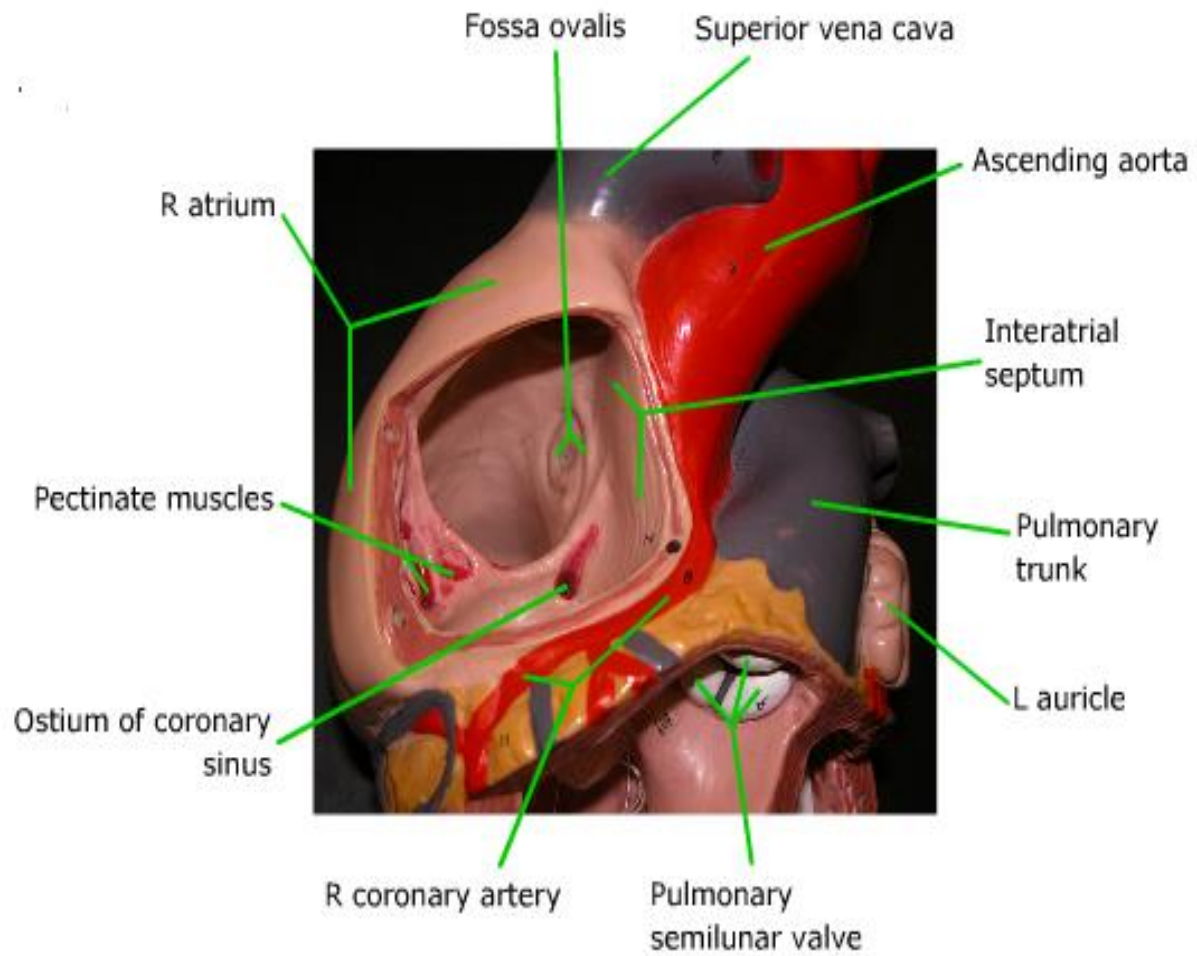




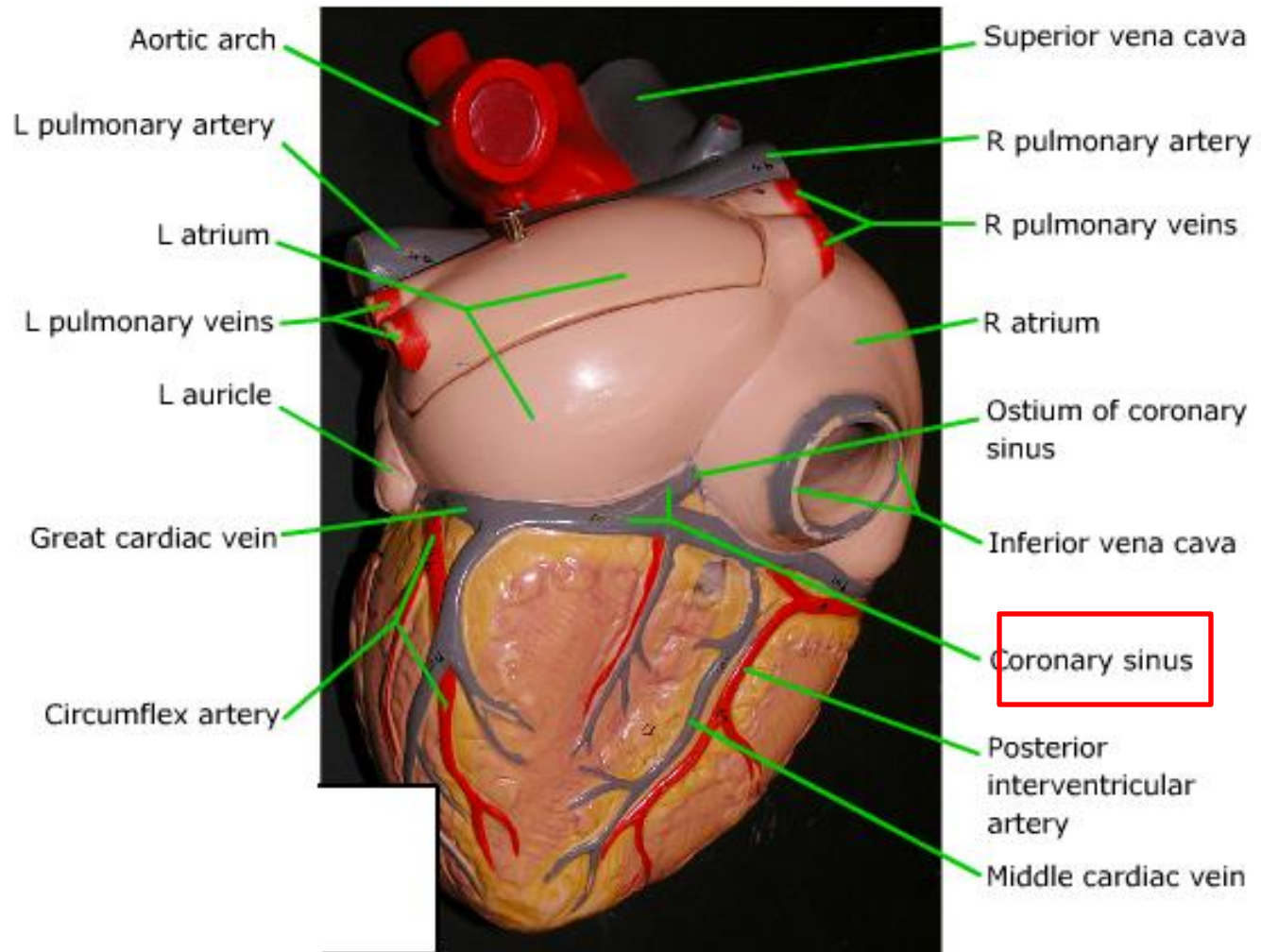
# Heart: anterior view





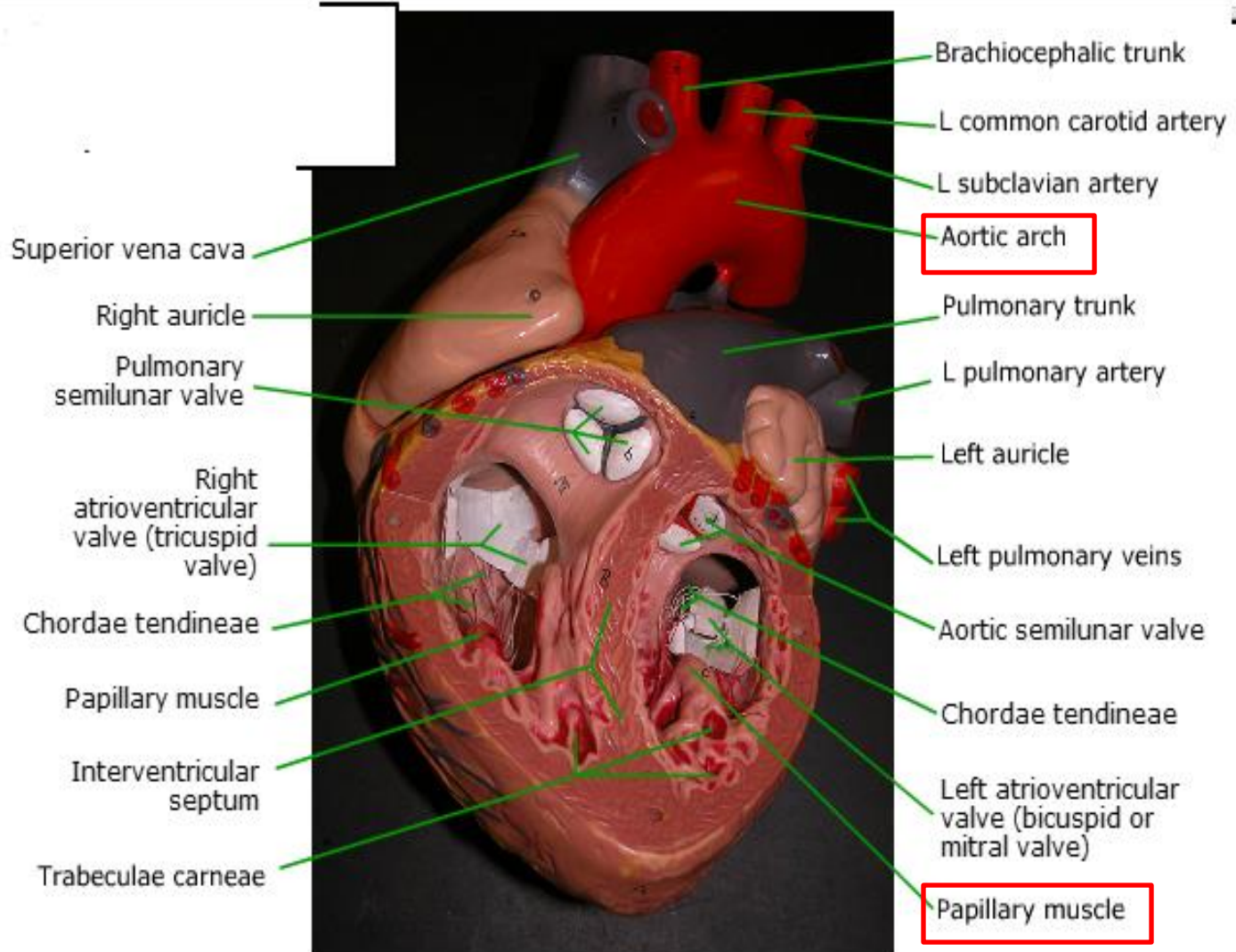


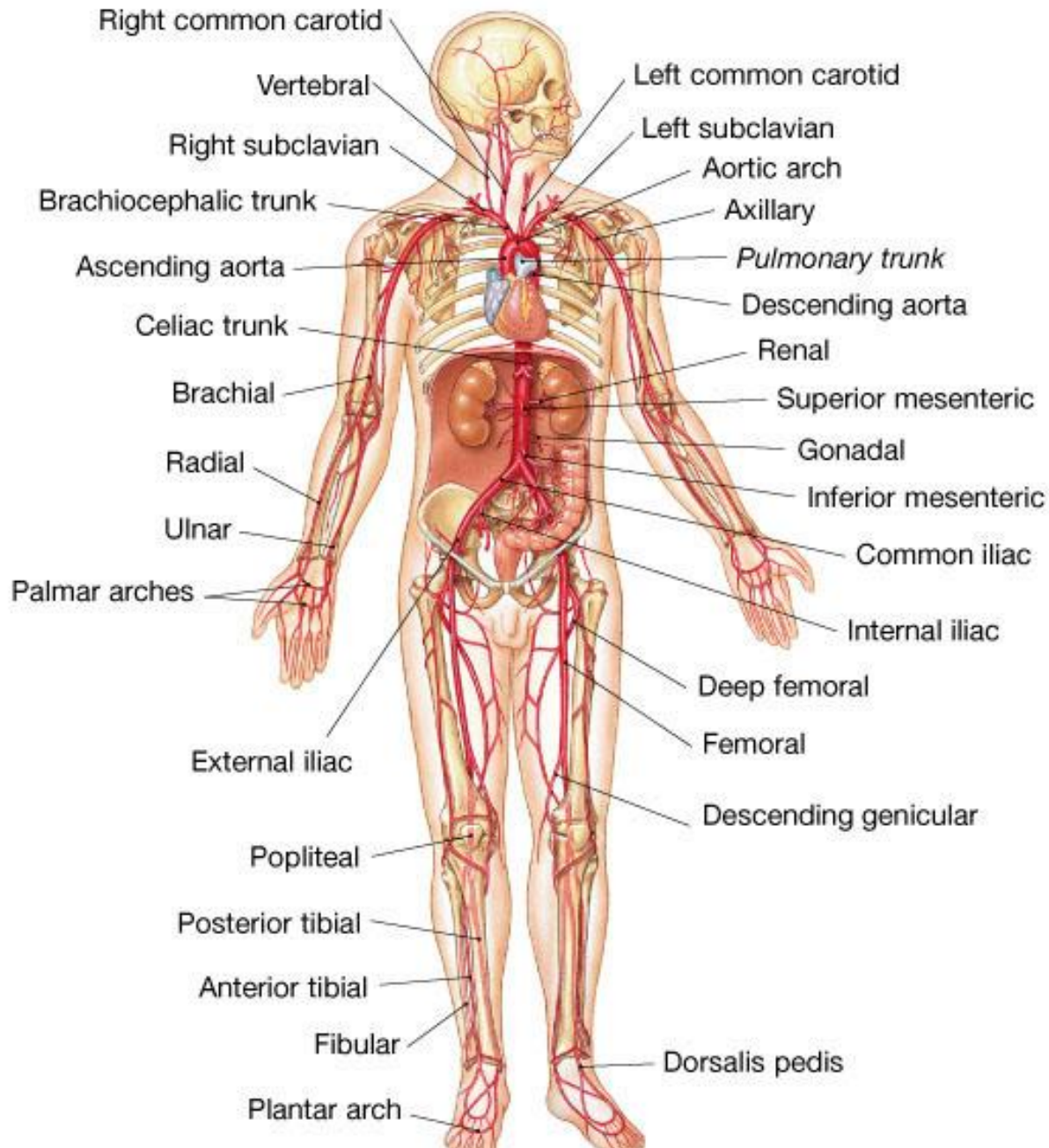
## Heart: posterior

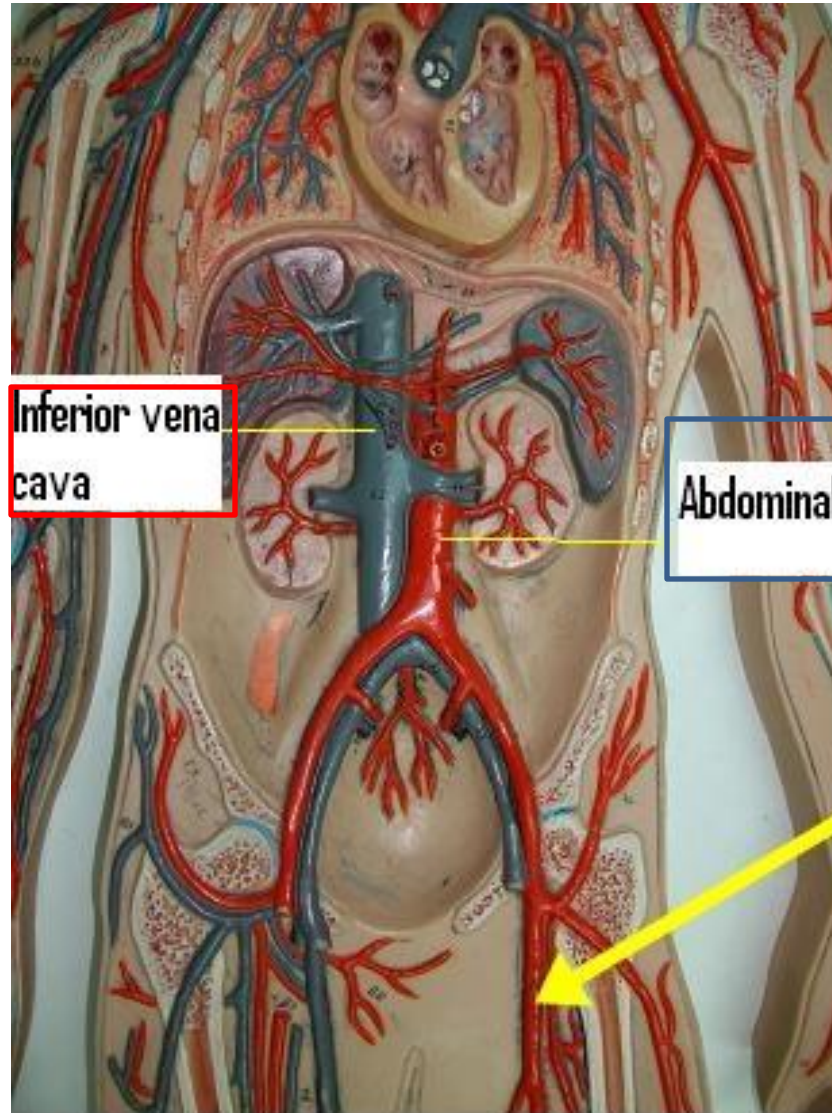




# Heart: internal view of ventricles



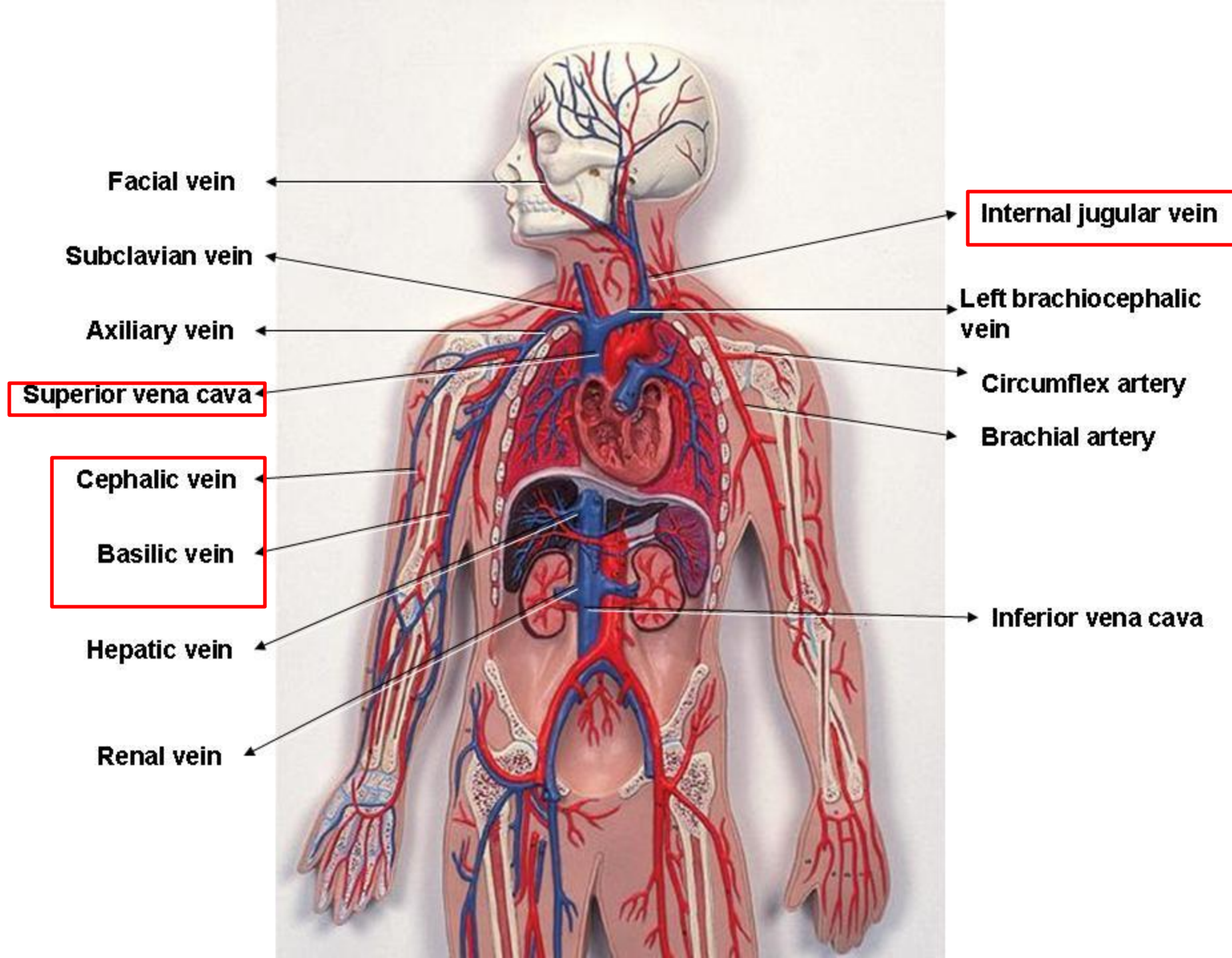


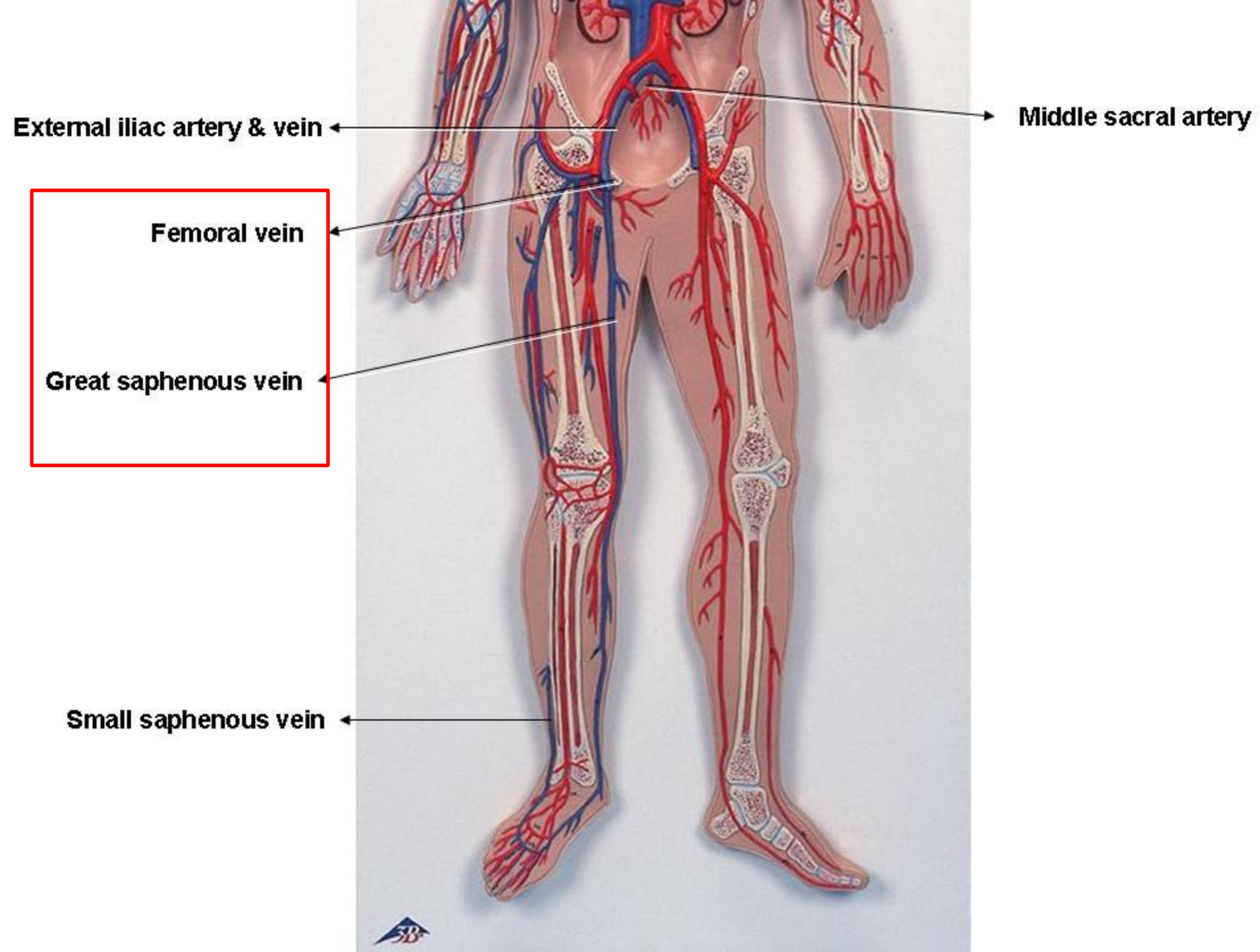


Inferior vena  
cava

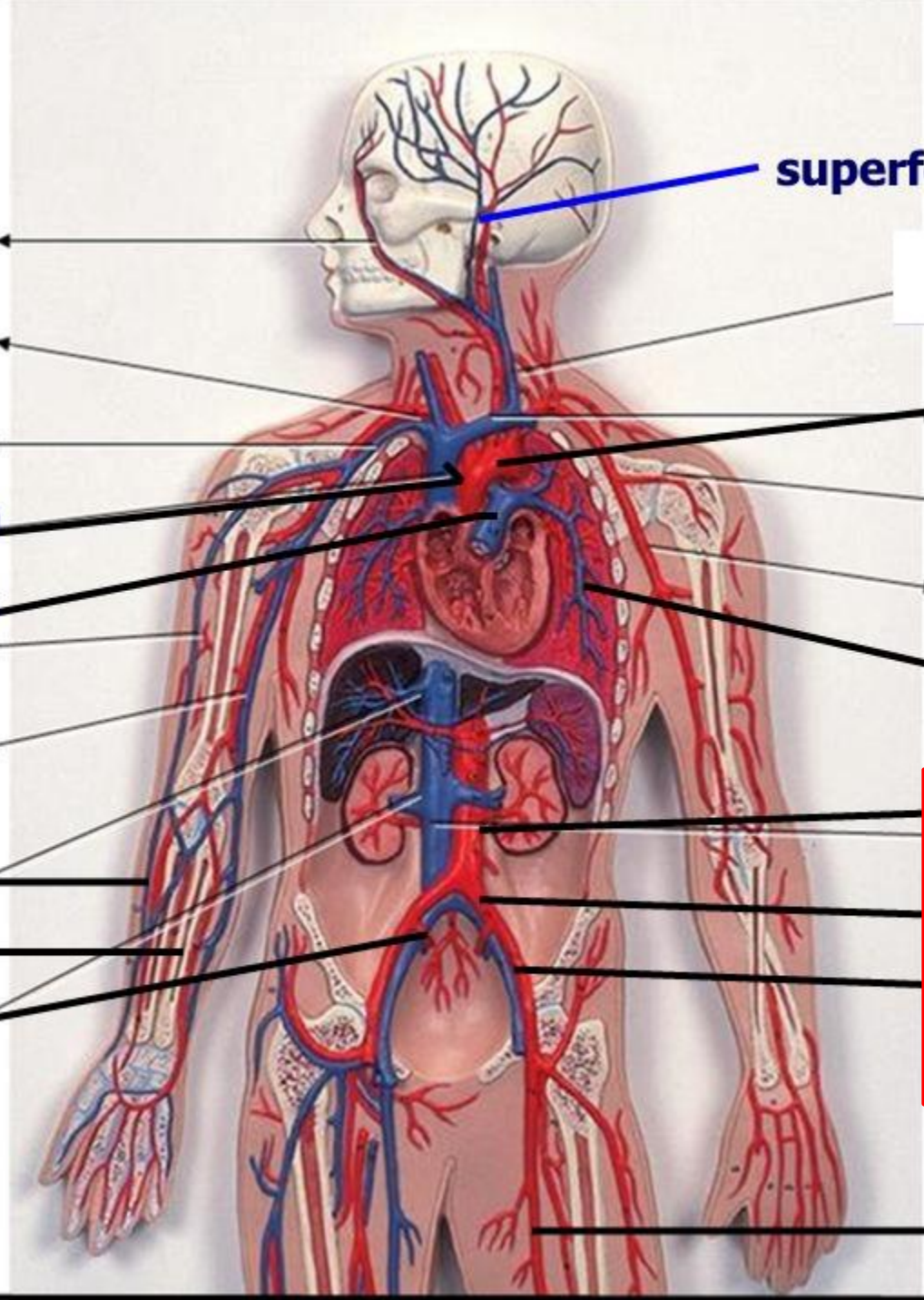
Abdominal aorta











**superficial temporal a**

**Facial a**

**arch of aorta**

**ascending aorta**

**Circumflex artery**

**pulmonary trunk**

**Brachial artery**

**pulmonary artery**

**abdominal aorta**

**radial a**

**common iliac a**

**ulnar a**

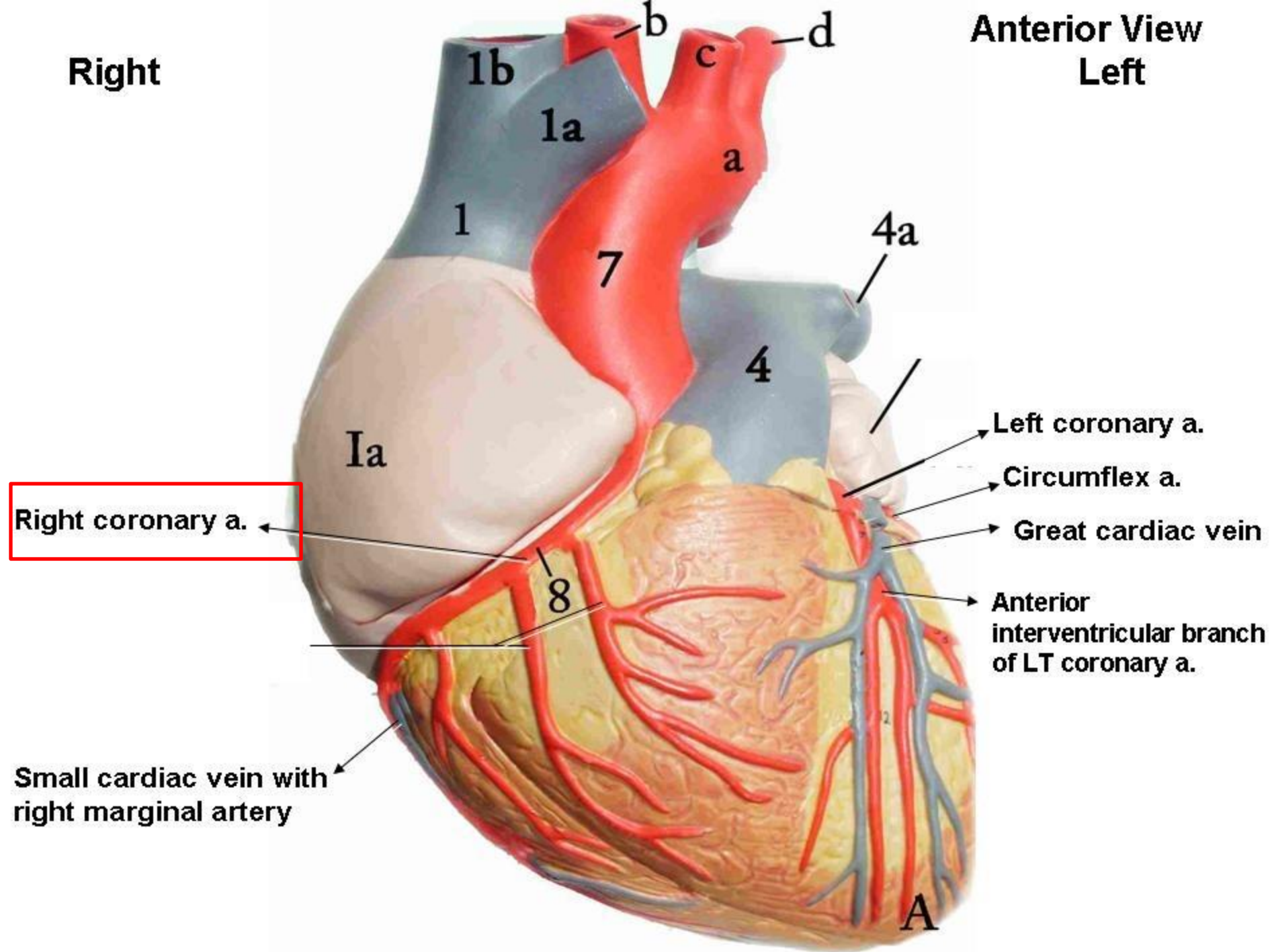
**external i a**

**internal i a**

**femoral a**

Right

Anterior View  
Left

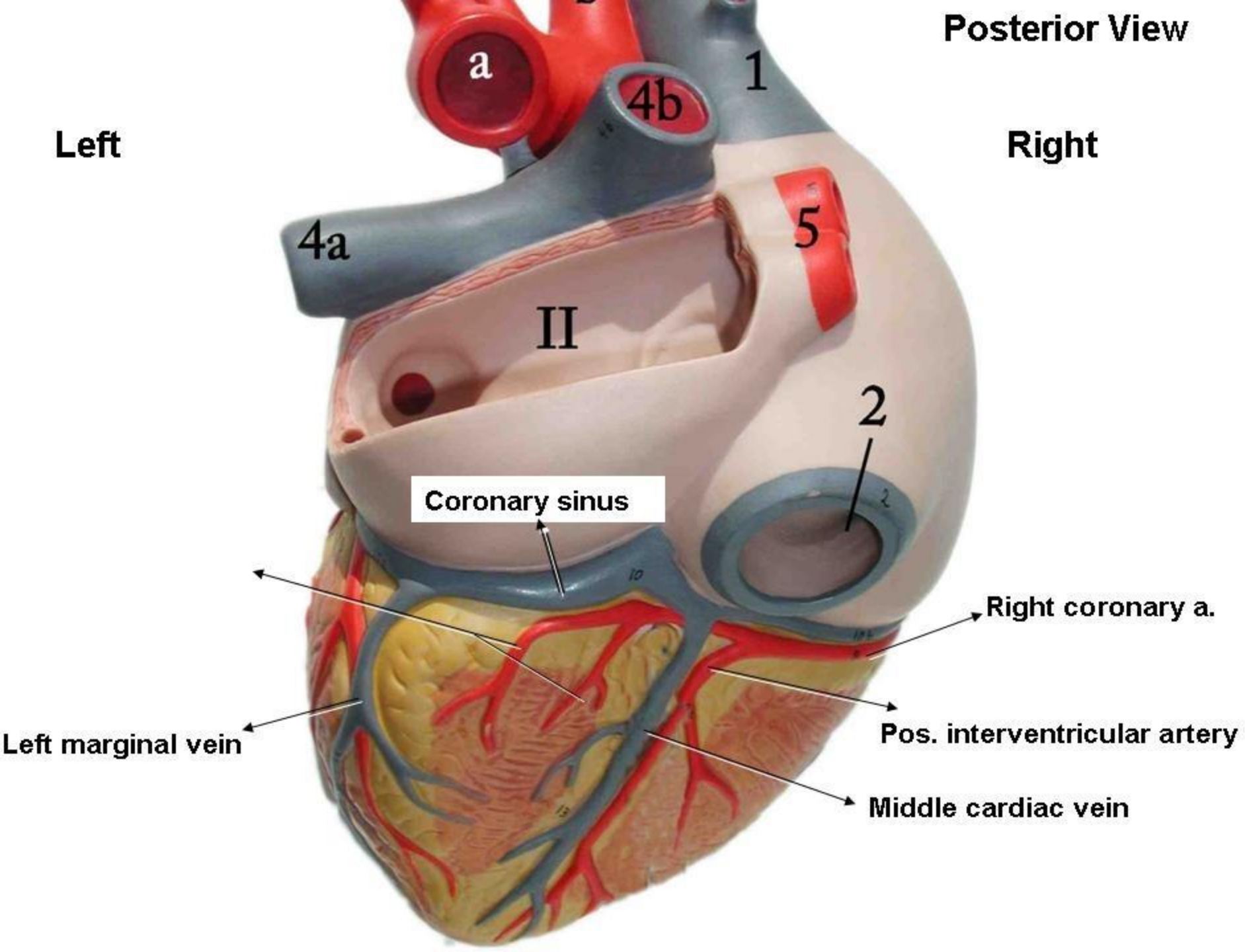




Posterior View

Left

Right



Coronary sinus

Right coronary a.

Pos. interventricular artery

Middle cardiac vein

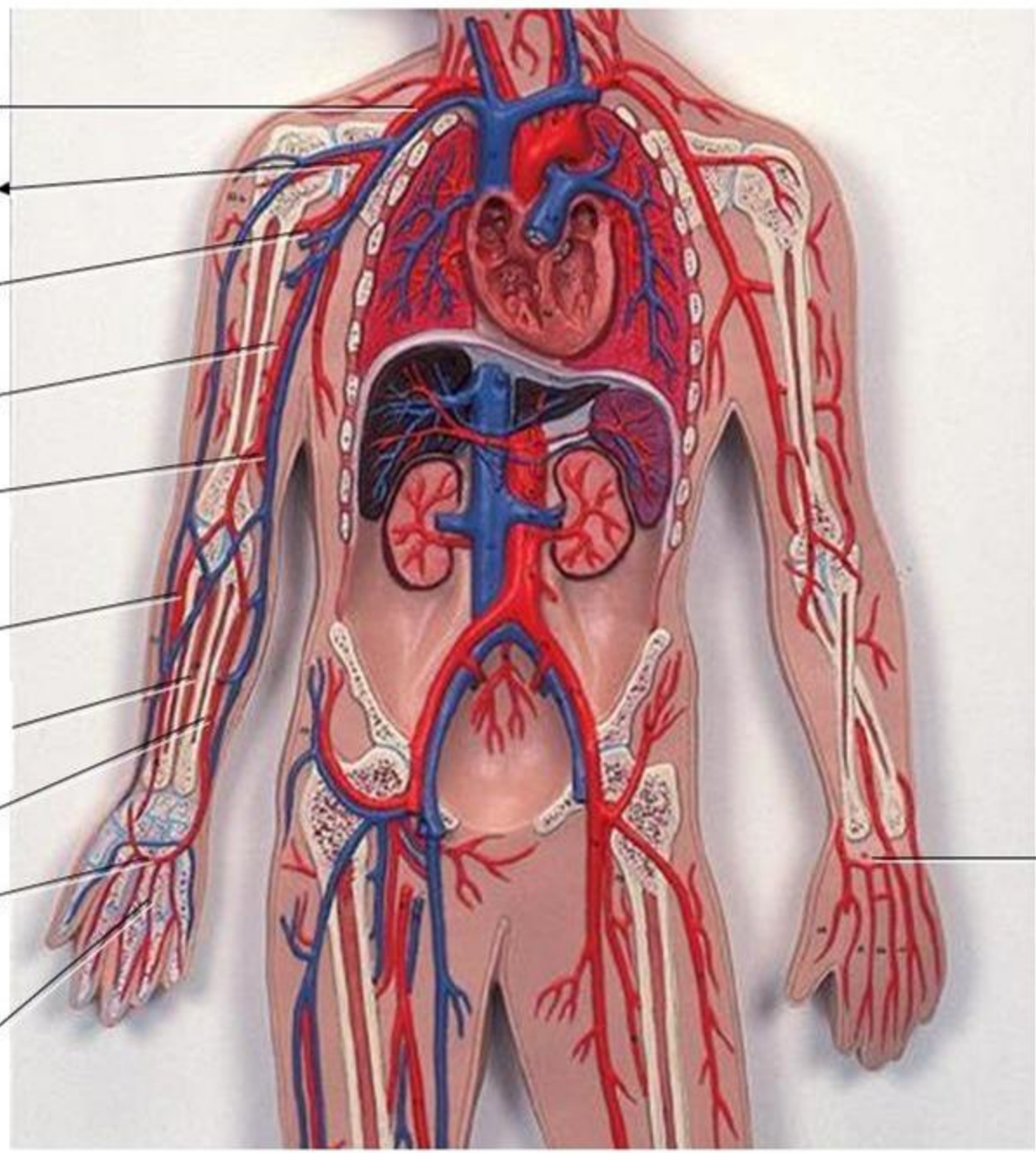
Left marginal vein

**Axillary artery**

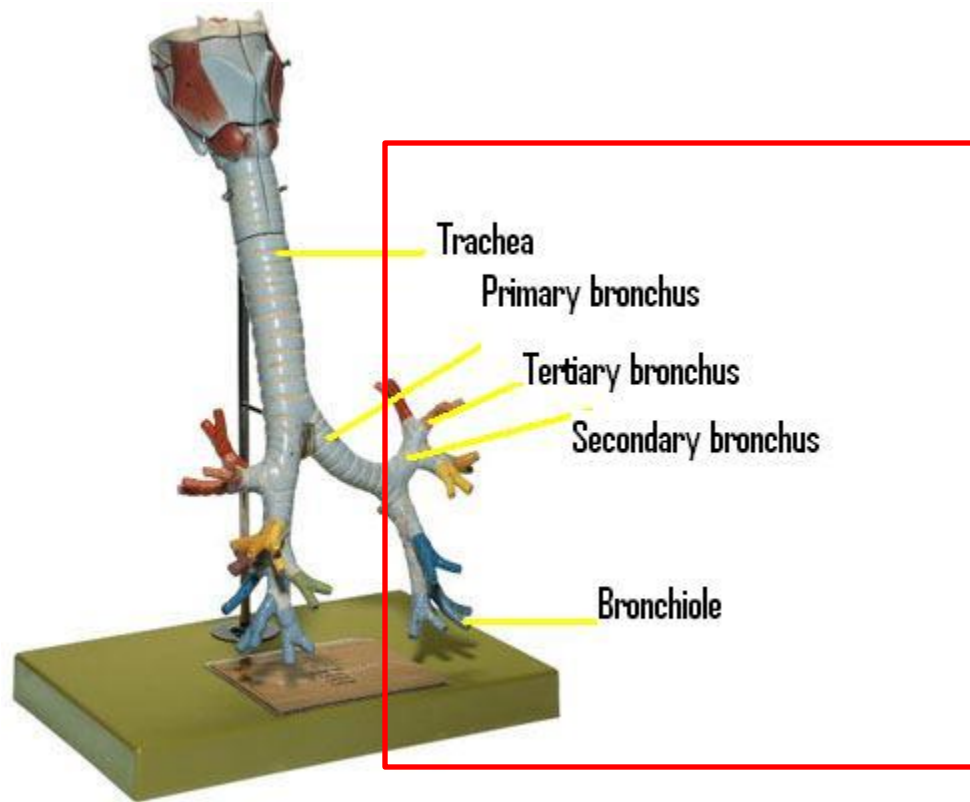
**Brachial artery**

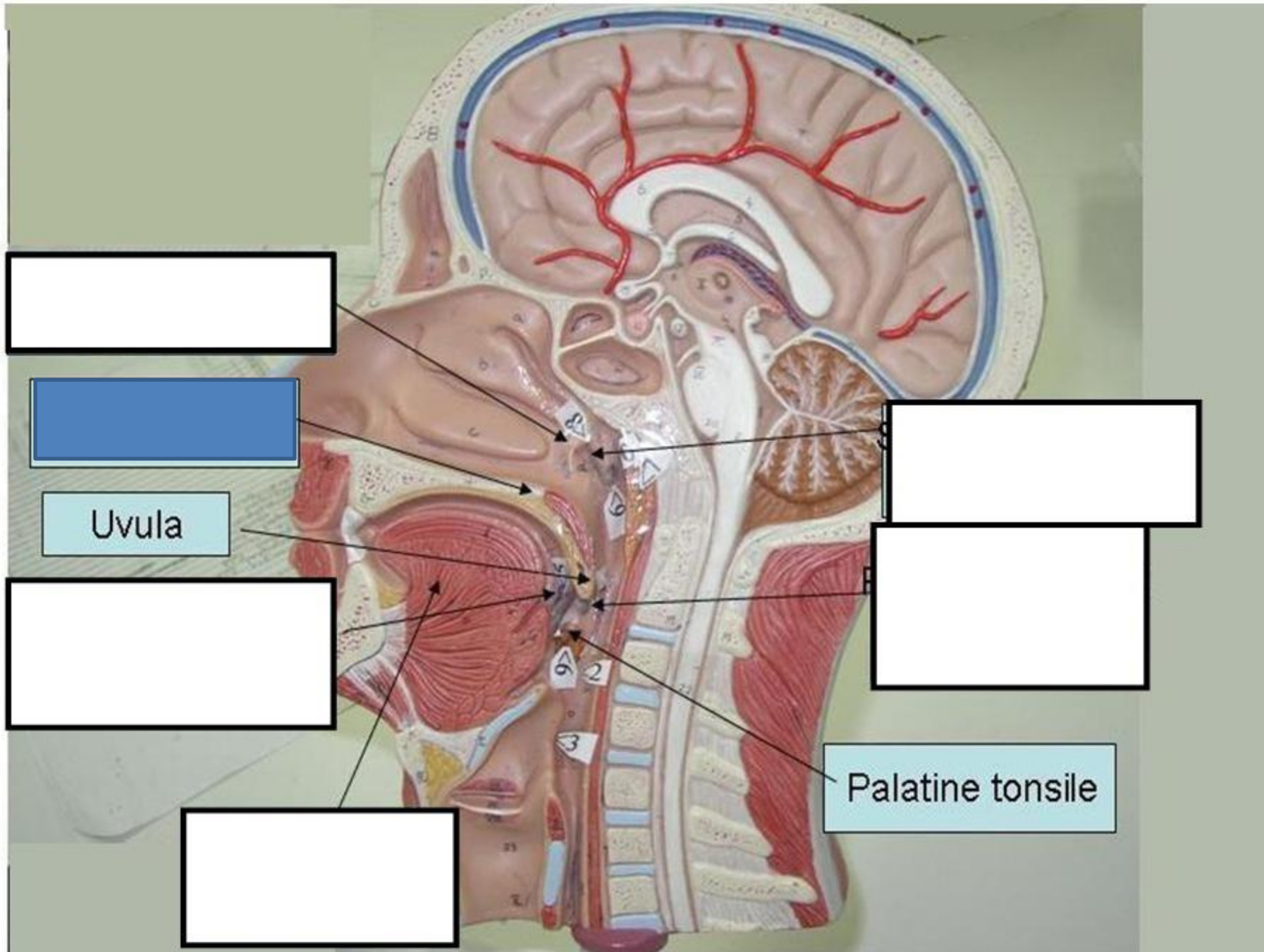
**Radial artery**

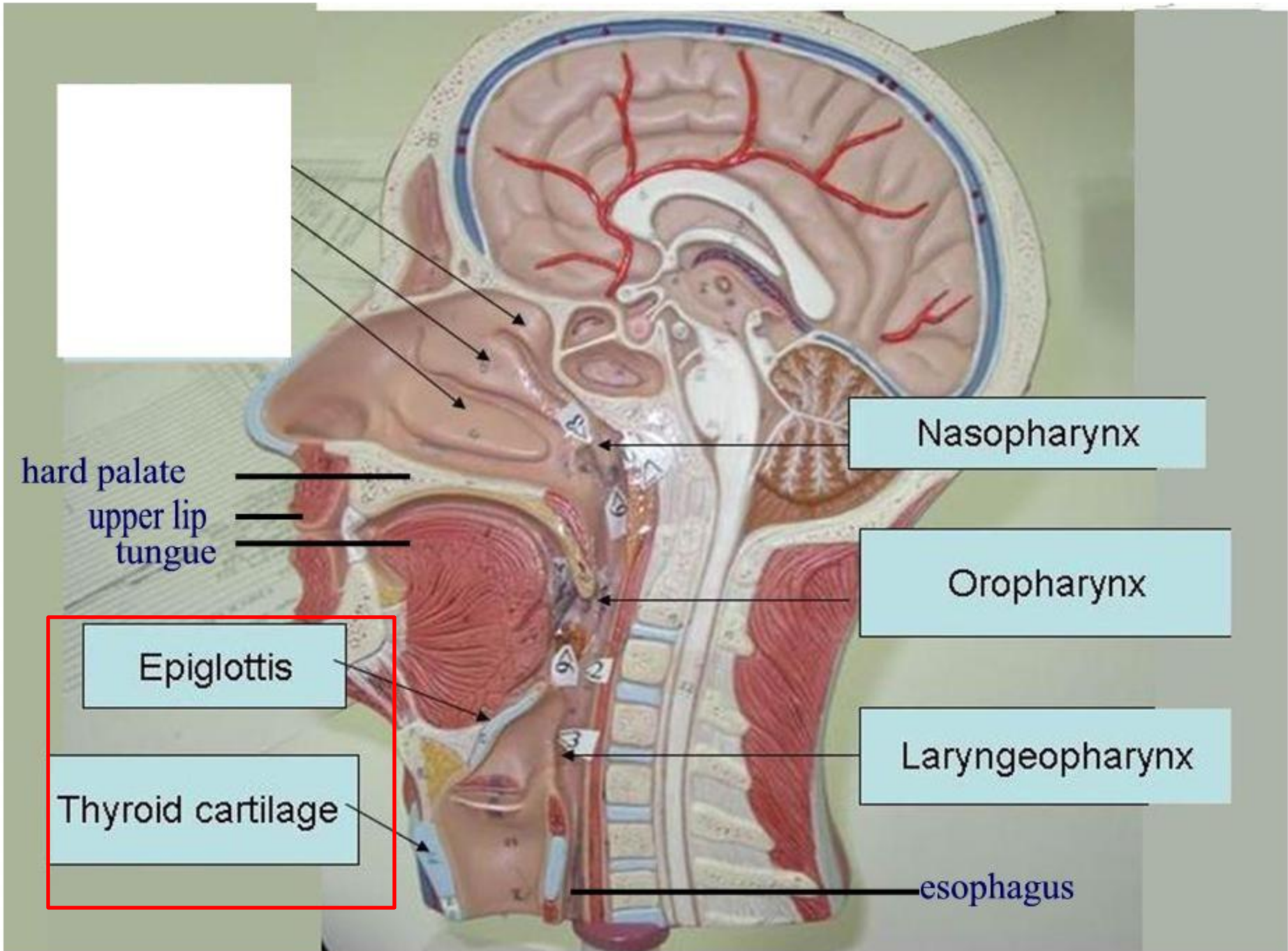
**Ulnar artery**











hard palate  
upper lip  
tongue

Nasopharynx

Oropharynx

Laryngeopharynx

esophagus

Epiglottis

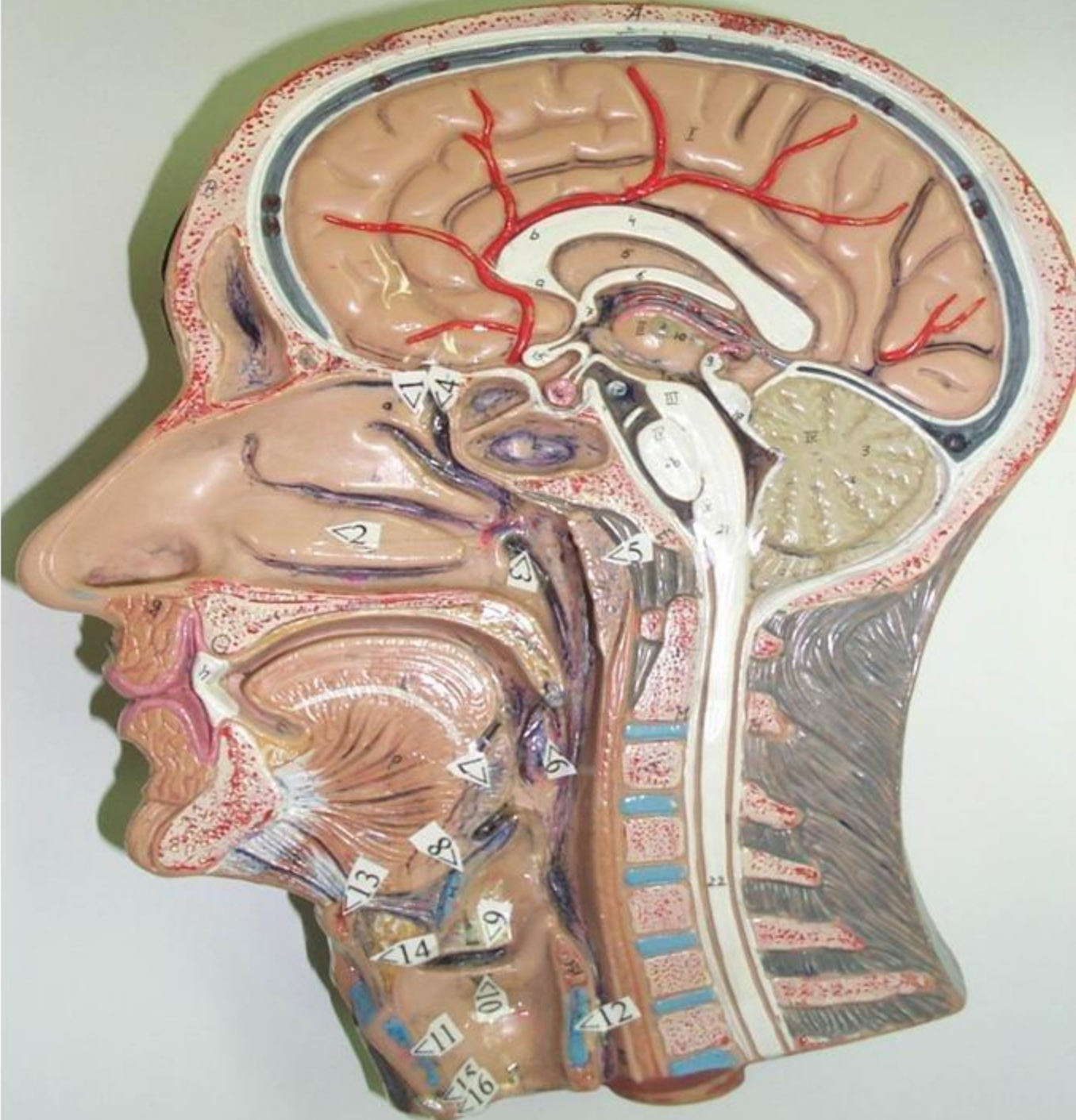
Thyroid cartilage



**5. Pharyngeal tonsil**

**6. Palatine tonsil**

**7. Lingual tonsil**





1. Superior concha
2. Inferior concha
3. Eustachian tube  
(Pharyngeotympanic tube)

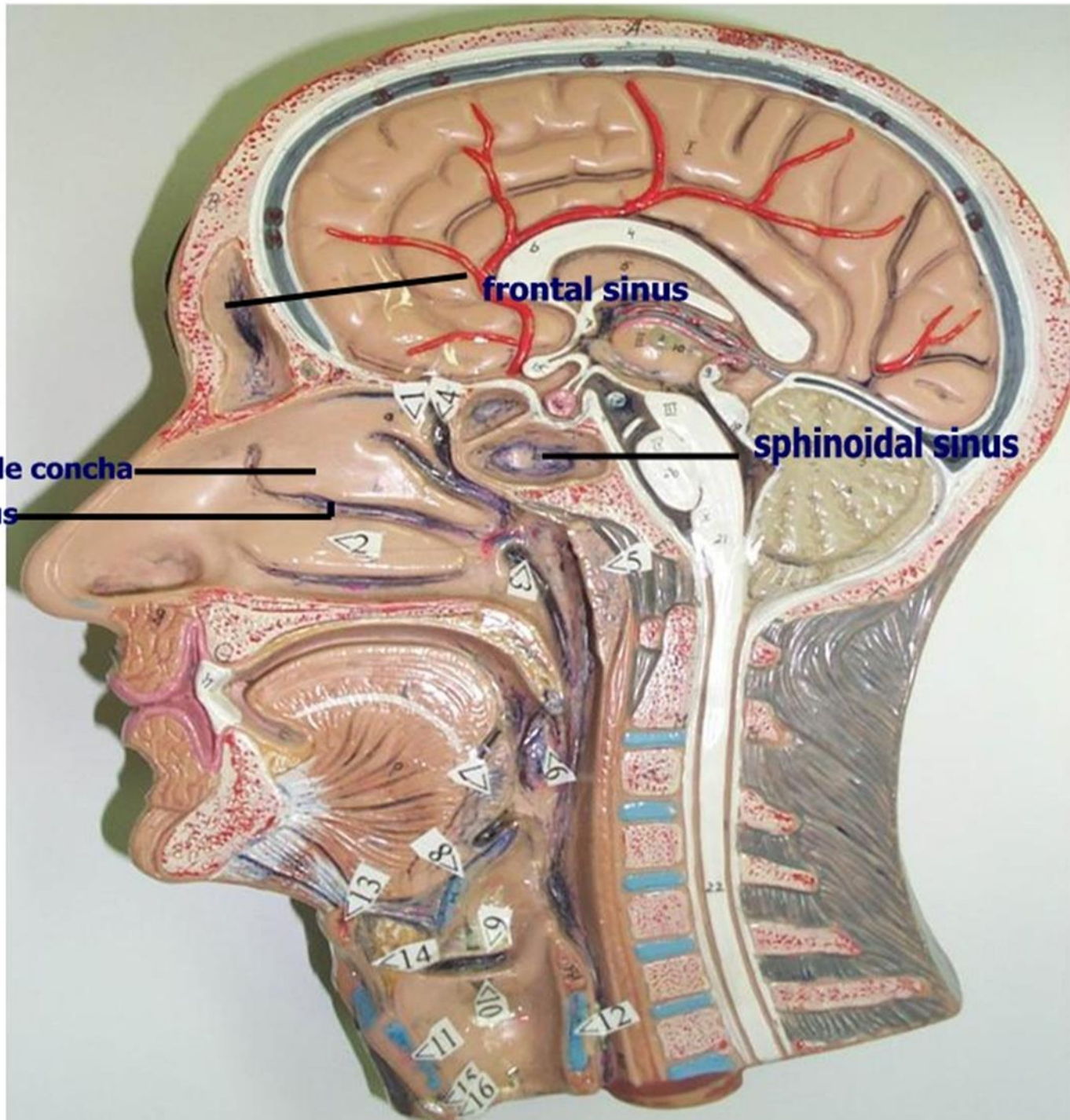
5. Pharyngeal tonsil
6. Palatine tonsil
7. Lingual tonsil
8. Epiglottis
9. False vocal cord
10. True vocal cord
11. Thyroid cartilage
12. Cricoid cartilage

**middle concha**

**middle meatus**

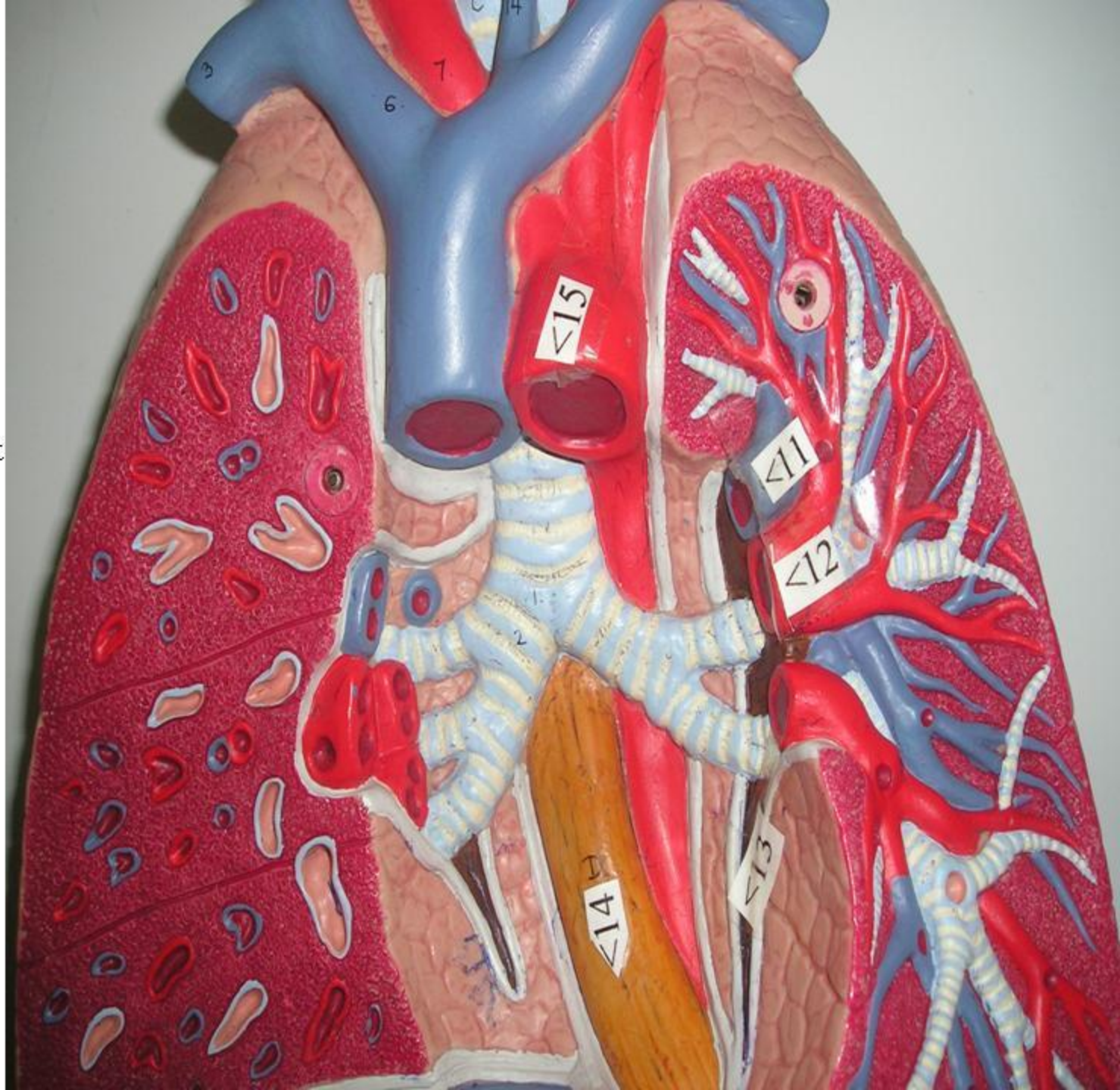
**frontal sinus**

**sphenoidal sinus**



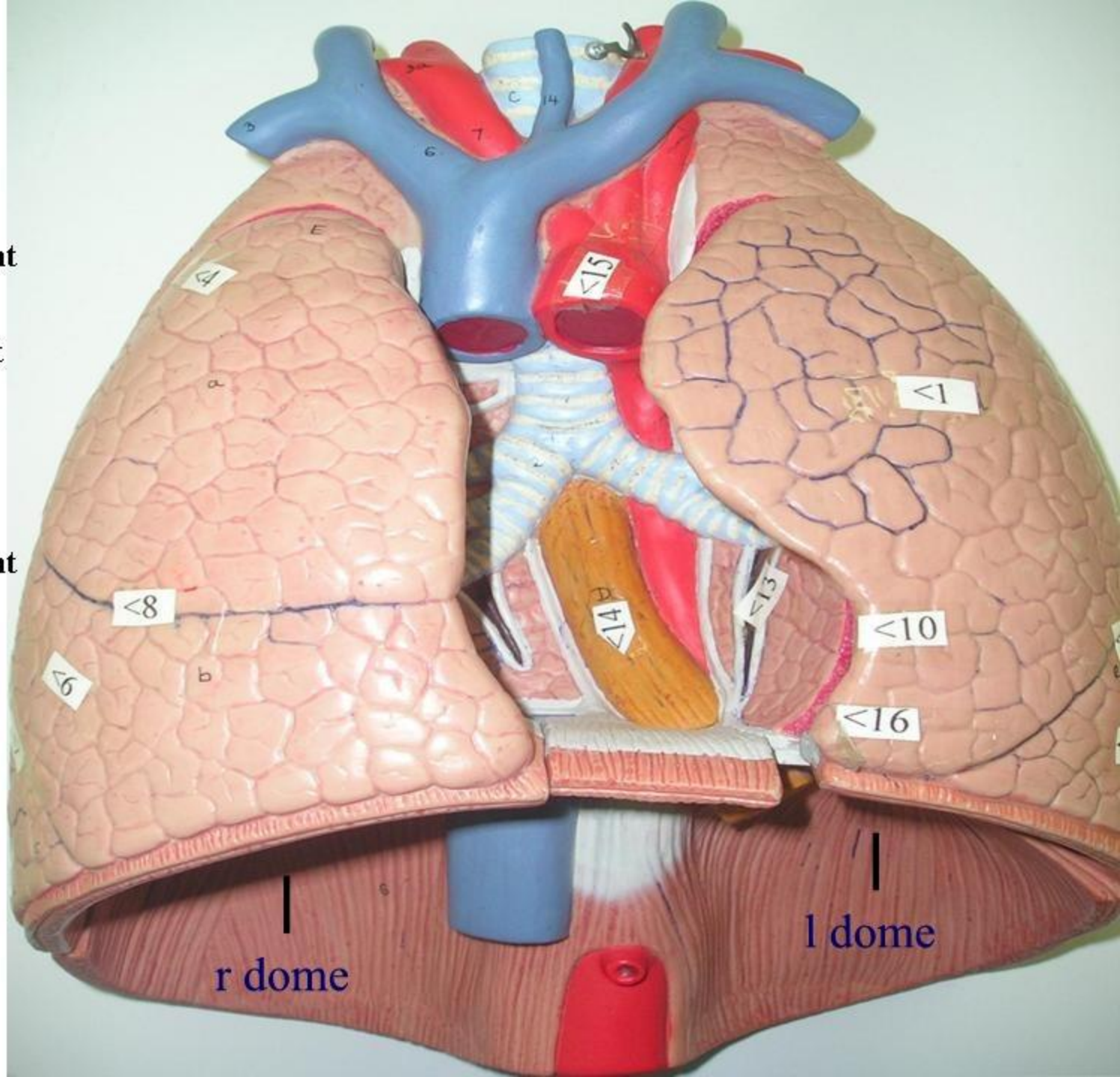


- 11. Pulmonary artery
- 12. Pulmonary vein
- 13. Pulmonary ligament
- 14. Esophagus
- 15. Aorta





- 1. Superior lobe of left lung
- 4. Superior lobe of right lung
- 5. Inferior lobe of right lung
- 8. Horizontal fissure
- 10. Cardiac notch
- 13. Pulmonary ligament
- 14. Esophagus
- 15. Aorta
- 16. Lingula



r dome

l dome

Pulmonary  
artery

Pulmonary vein

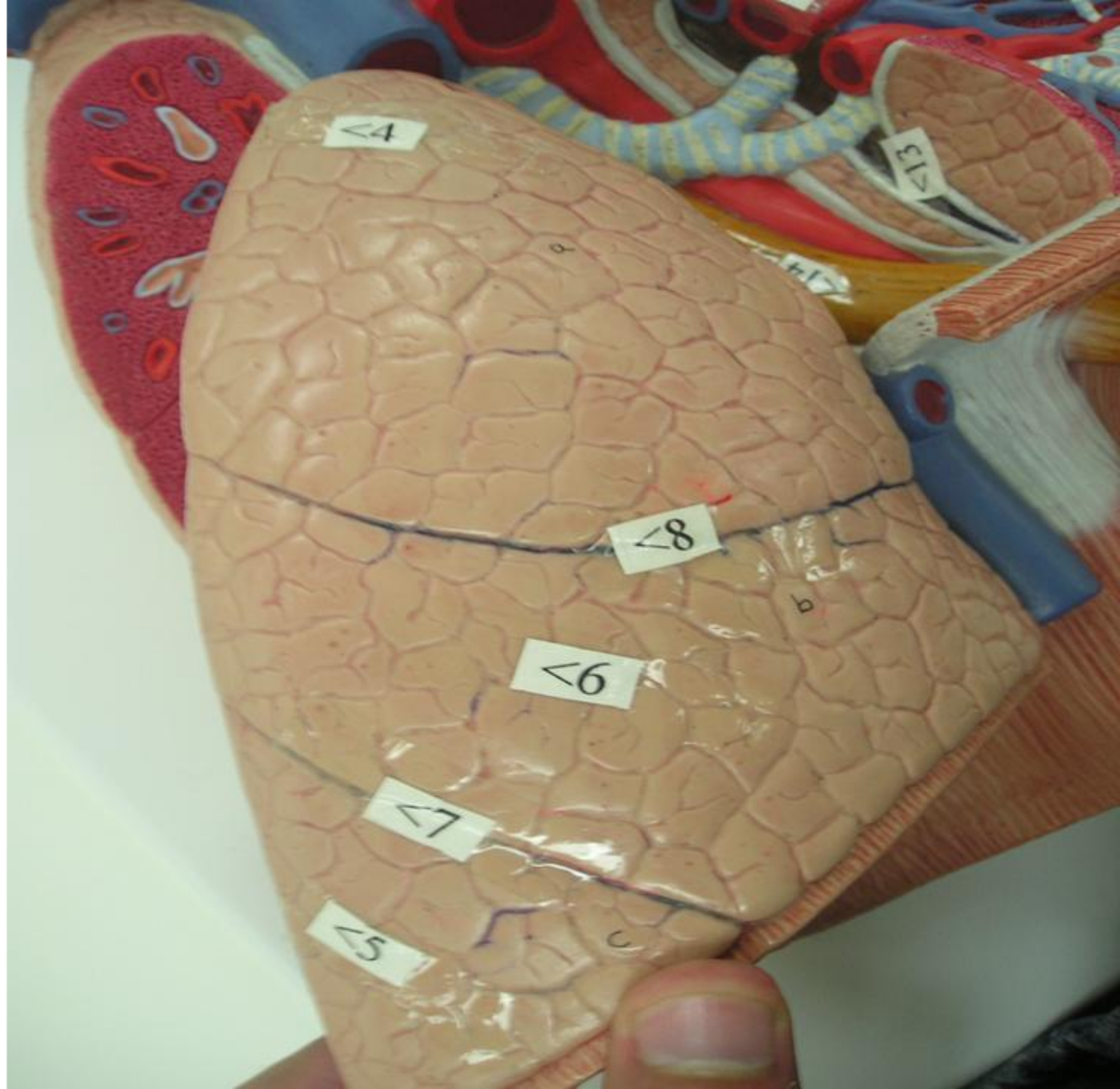Right dome of diaphragm

Left dome of diaphragm



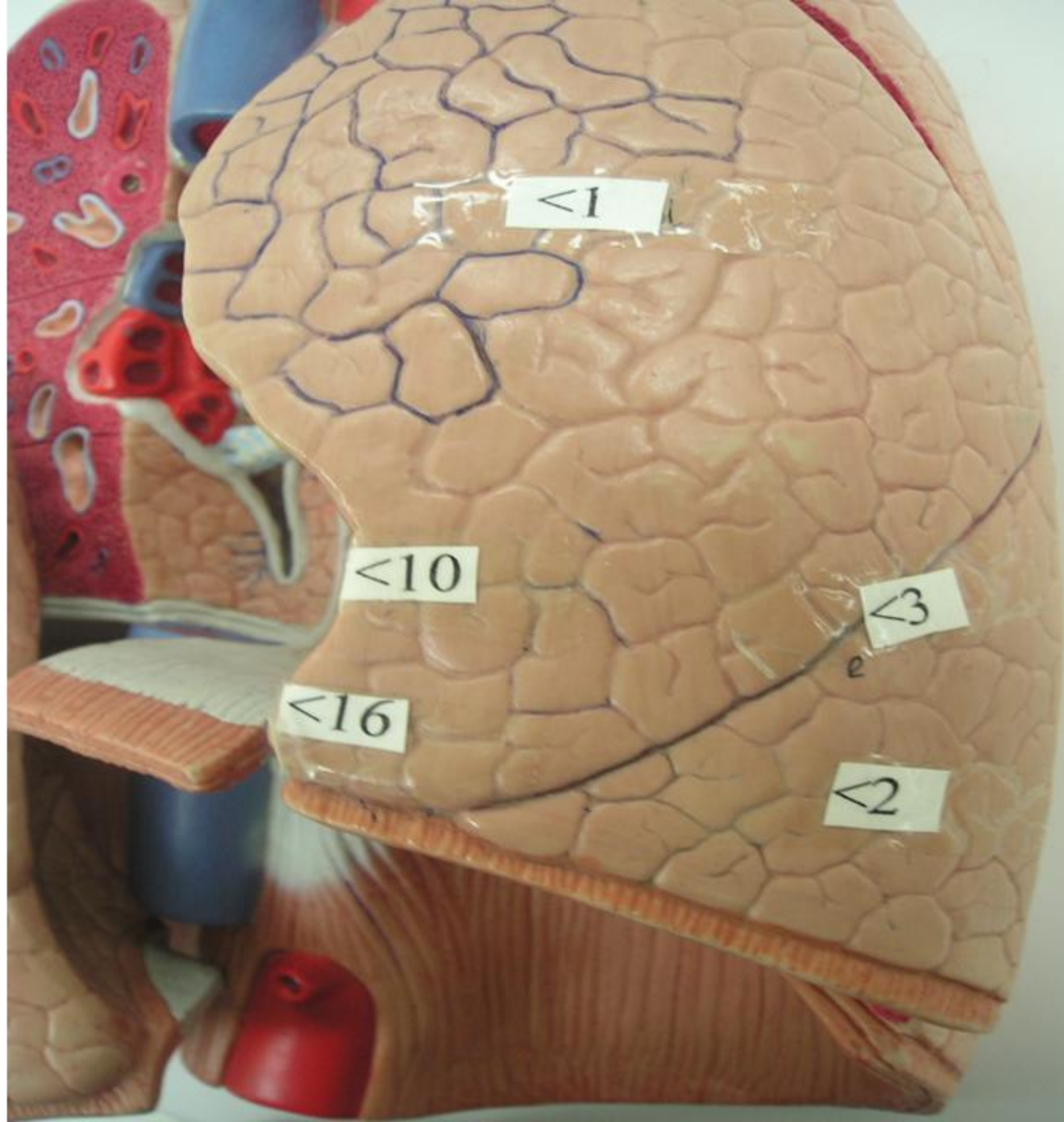
## Right lung

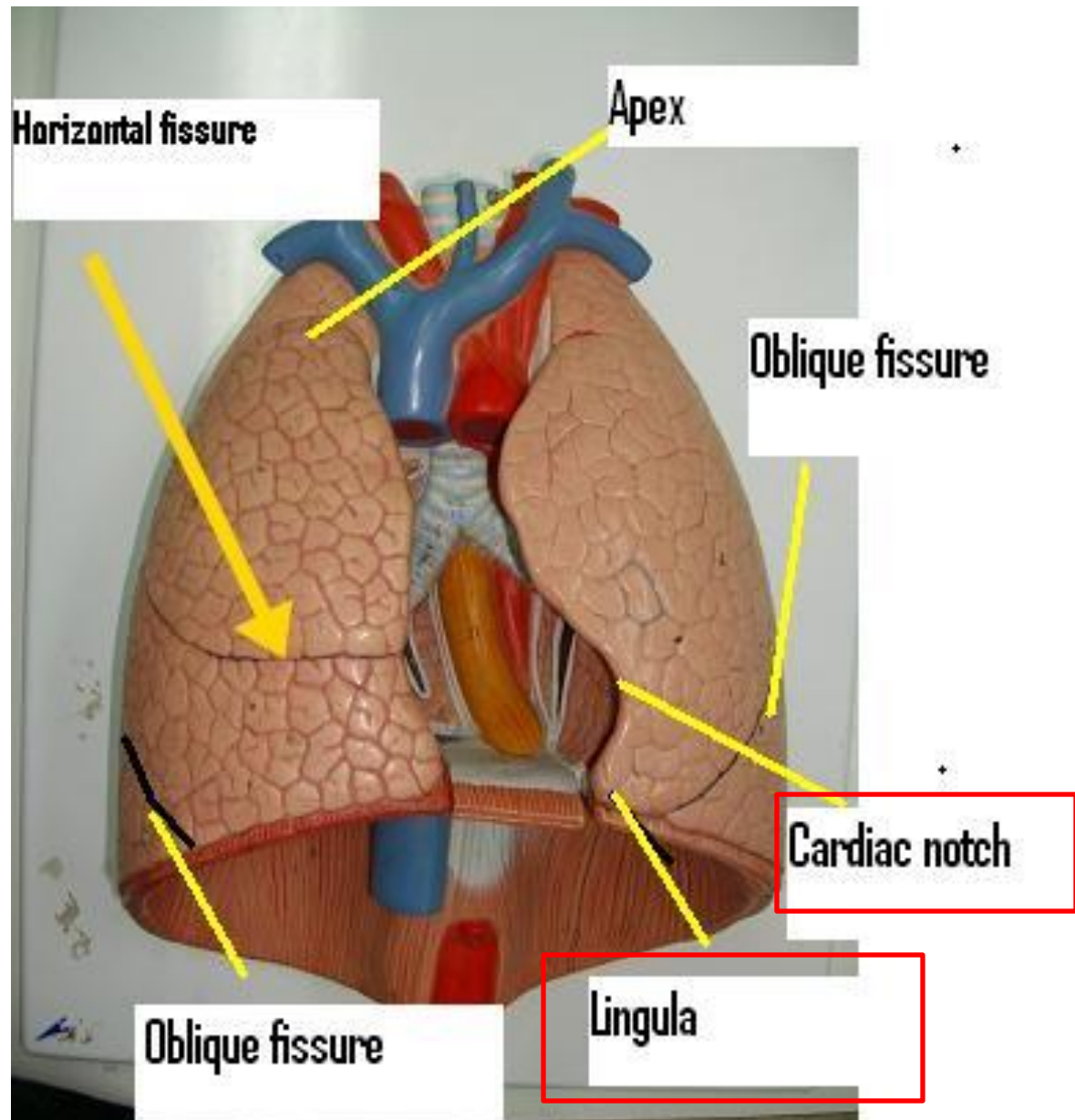
- 4.Superior lobe
- 5.Inferior lobe
- 6.Middle lobe
- 7.Oblique fissure
- 8.Horizontal fissure



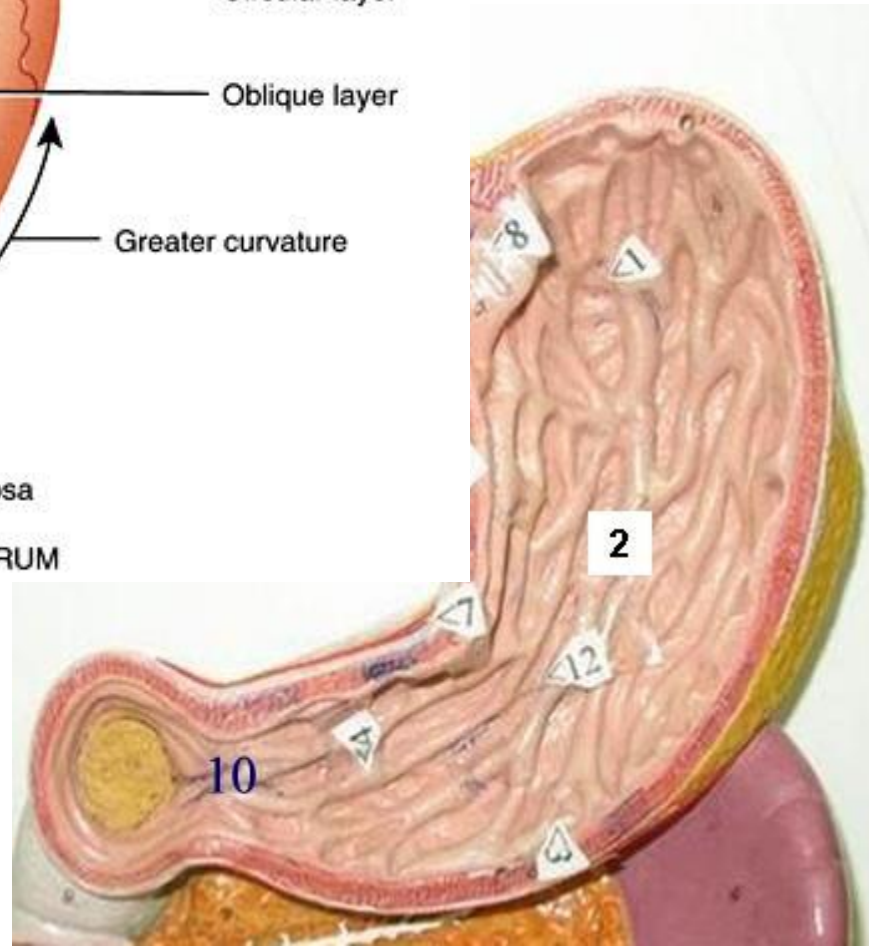
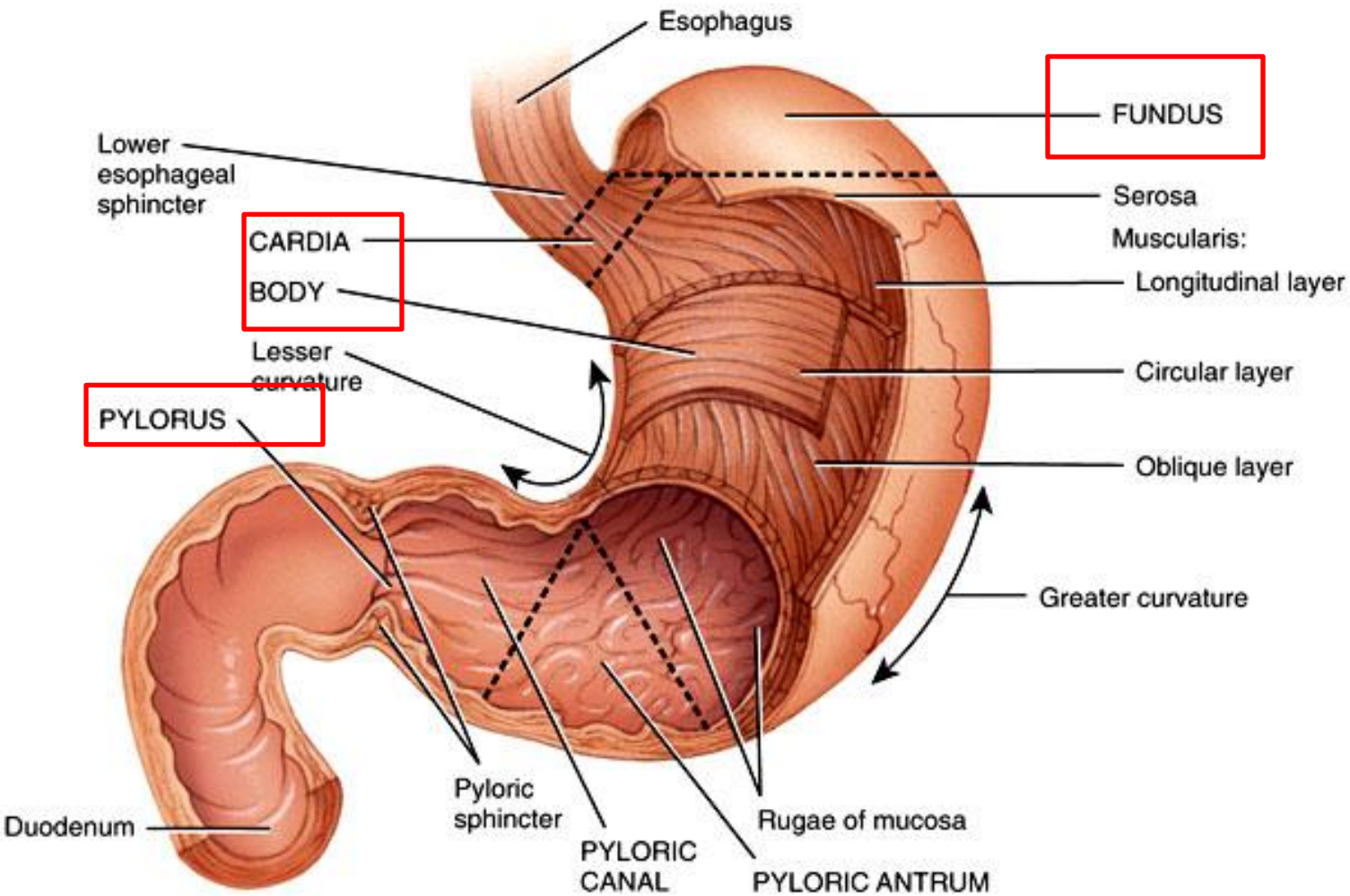
## Left lung

- 1.Superior lobe
- 2.Inferior lobe
- 3.Oblique fissure
- 10.Cardiac notch
- 16.lingula



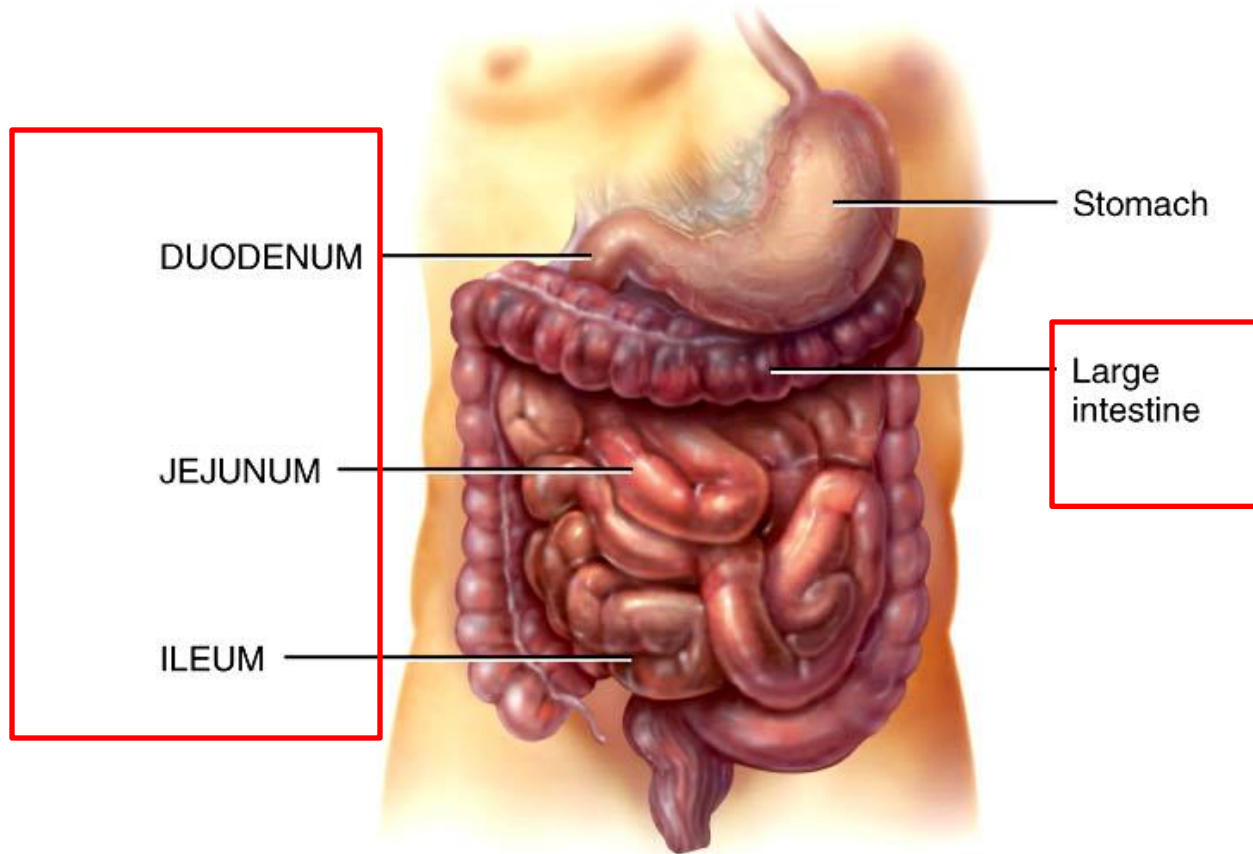






# Stomach

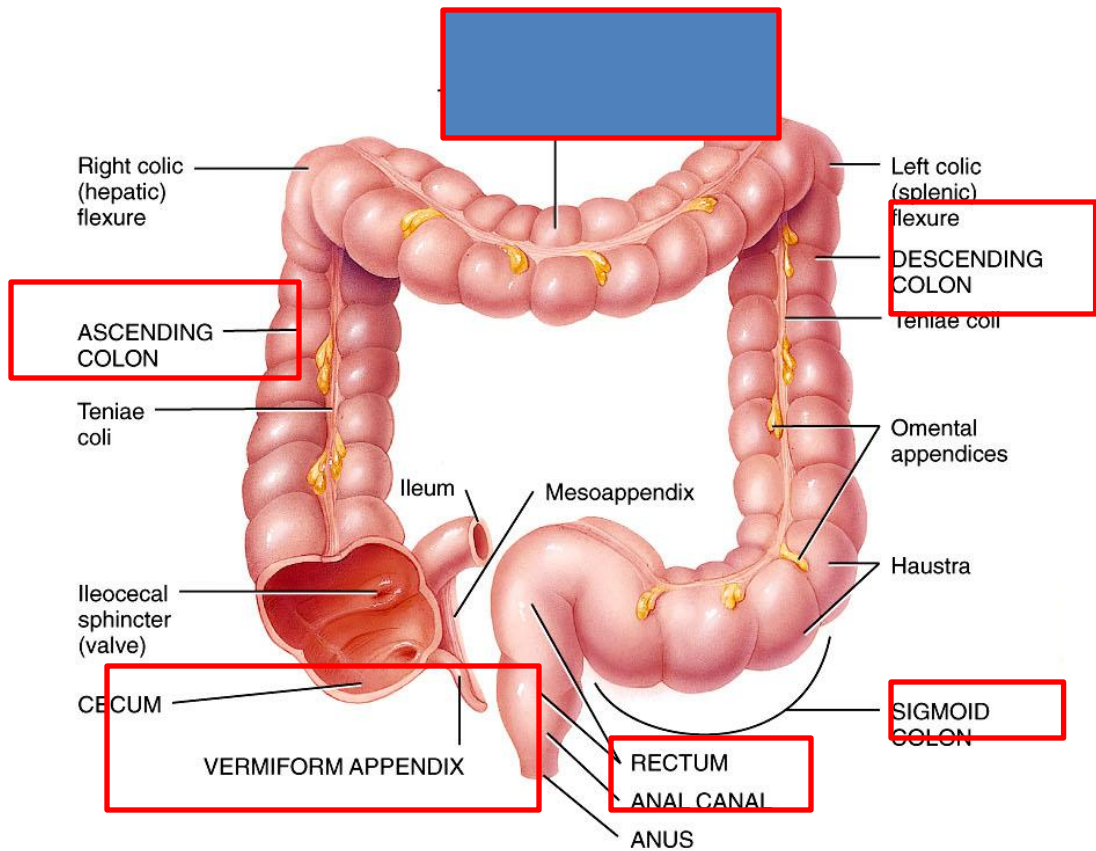




(a) Anterior view of external anatomy

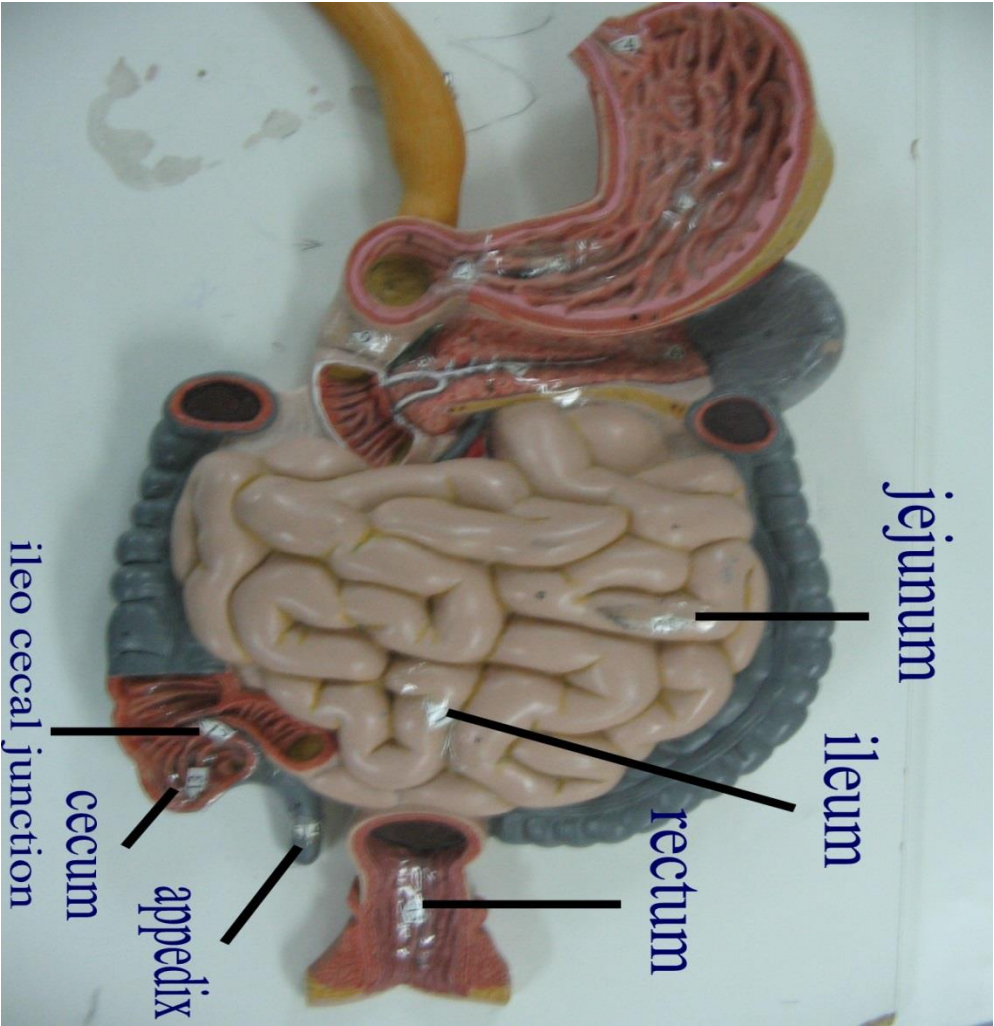
Figure 24.17 Tortora - PAP 12/e

Copyright © John Wiley and Sons, Inc. All rights reserved.



(a) Anterior view of large intestine showing major regions

Figure 24.22 Tortora - PAP 12/e  
 Copyright © John Wiley and Sons, Inc. All rights reserved.



jejunum

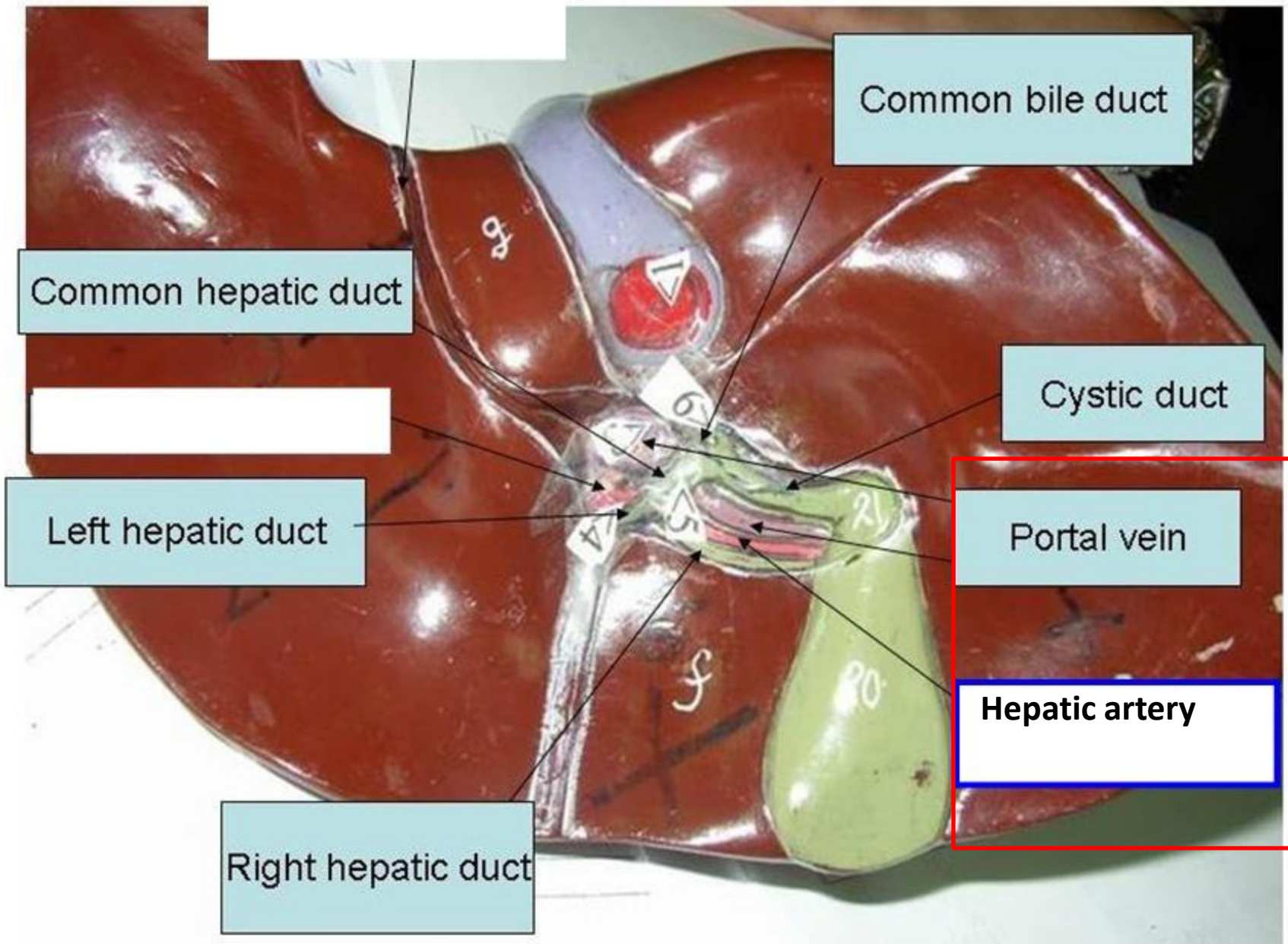
ileum

rectum

appendix

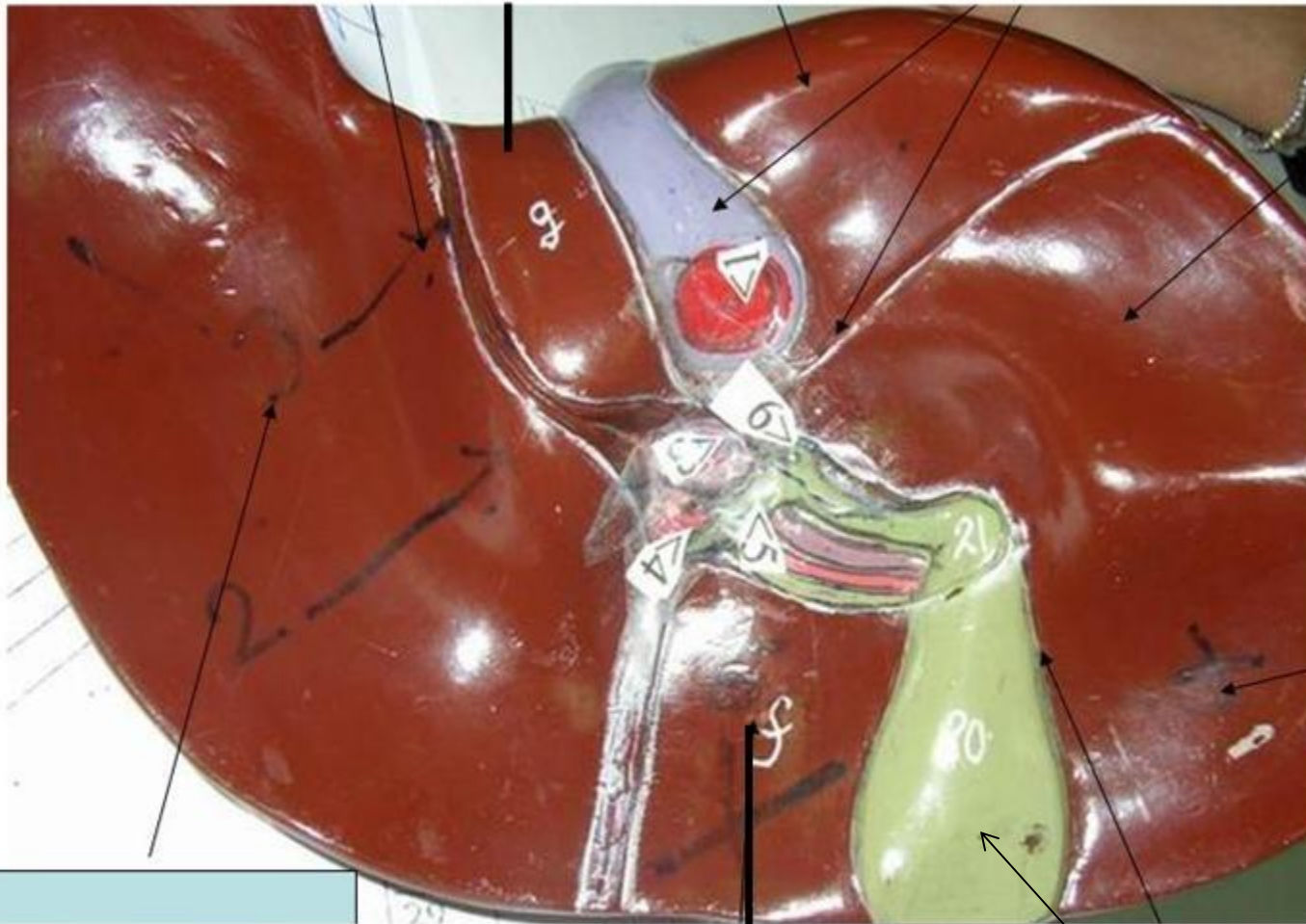cecum

ileo cecal junction






caudate lobe

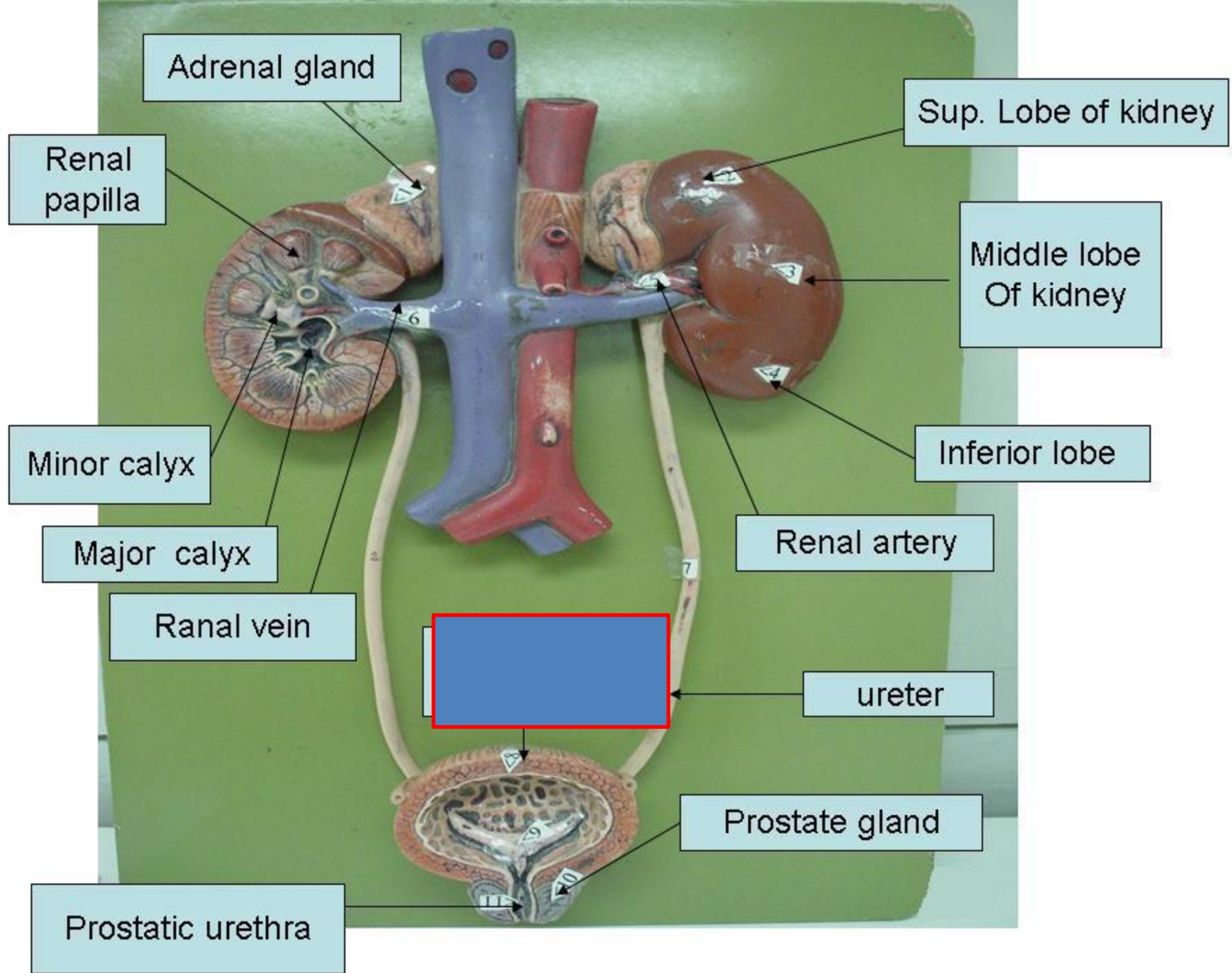


quadrate lobe

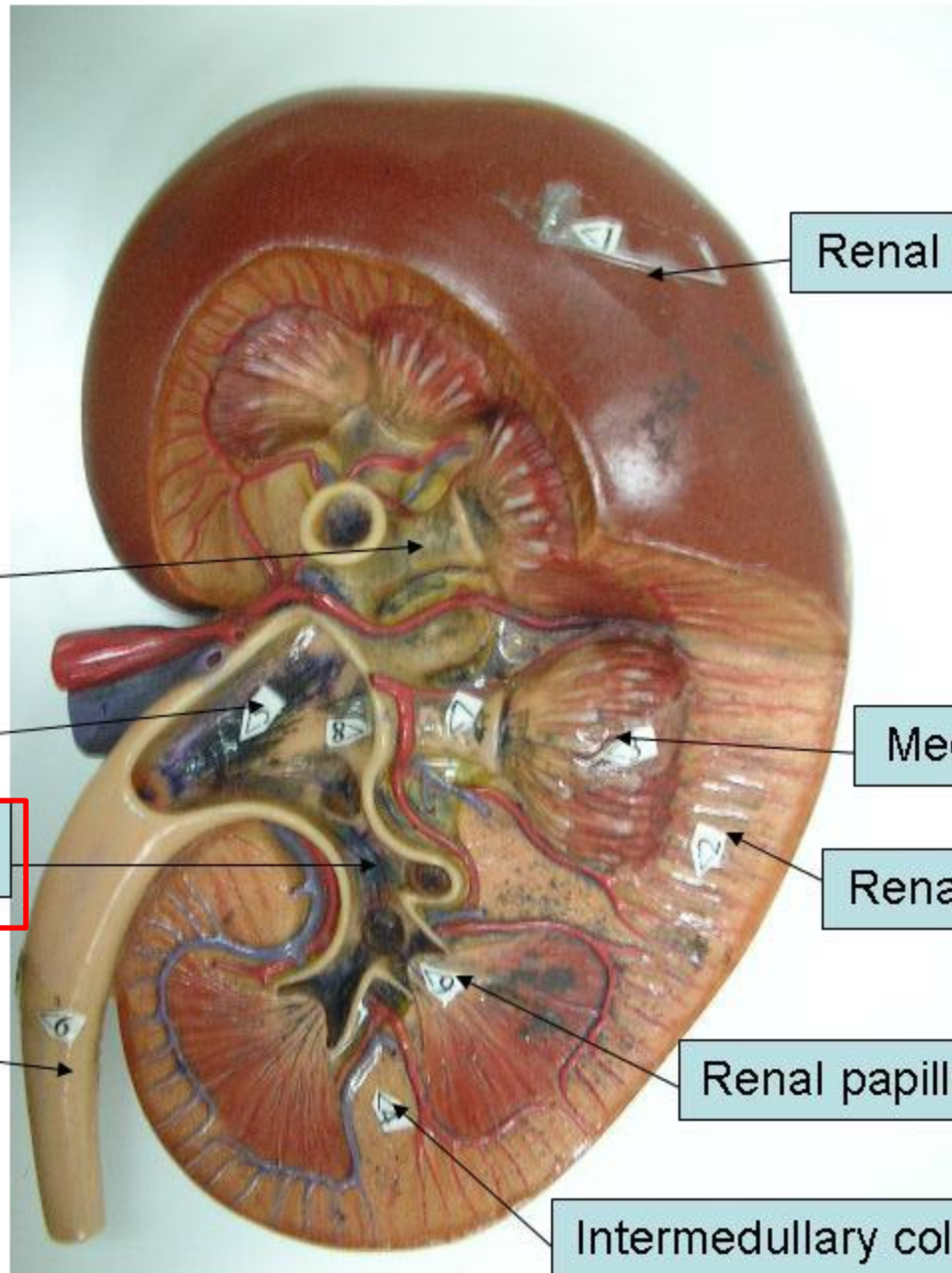
gallbladder



1=right lobe  
2=left lobe  
5=falciform lig.







Renal cortex

Minor calyx

Renal pelvis

Major calyx

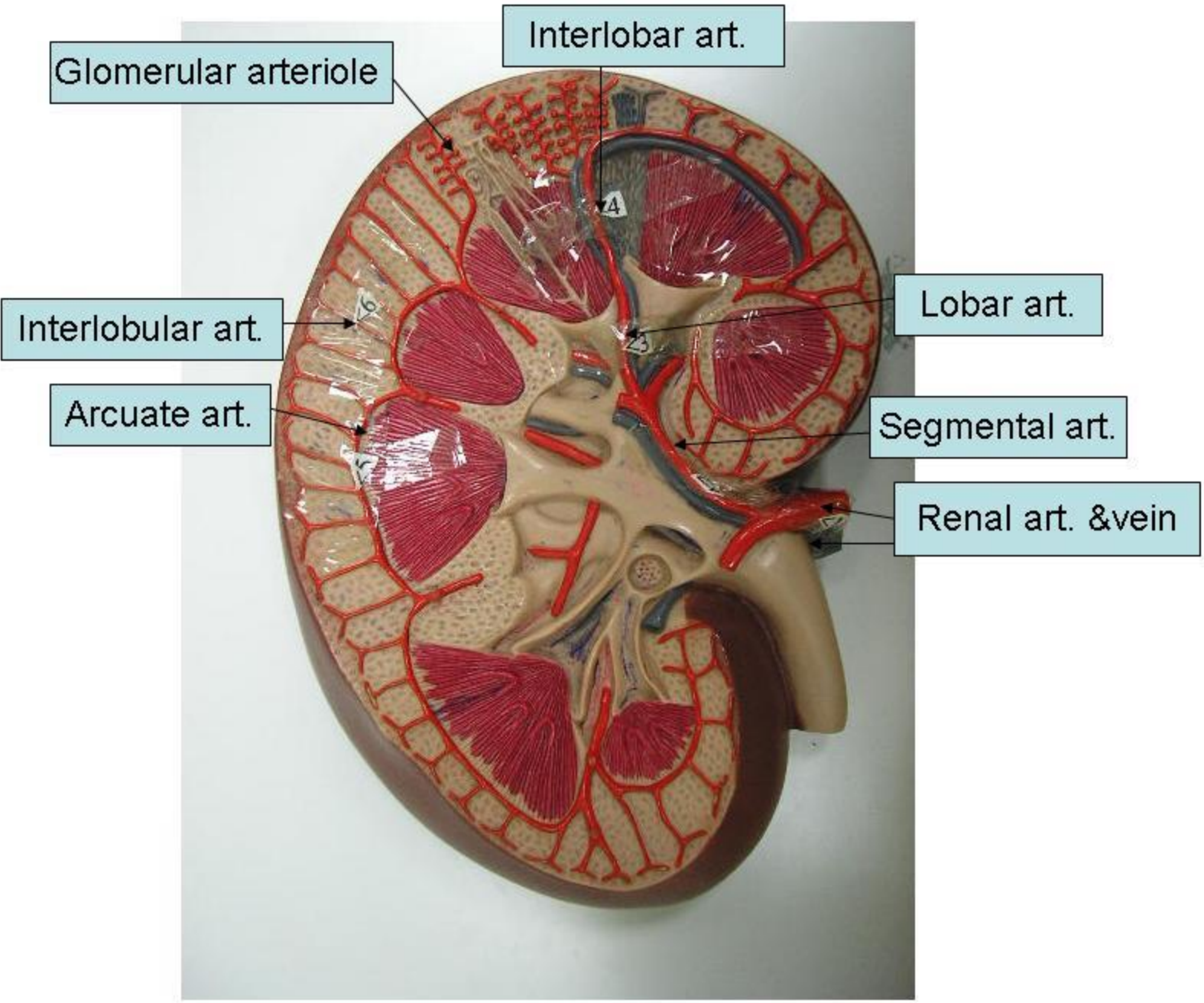
ureter

Medullary pyramids

Renal cortex

Renal papilla

Intermedullary columns



Urinary bladder

Ureter

Seminal vesicle

Ductus deferens

Prostate gland

Testis

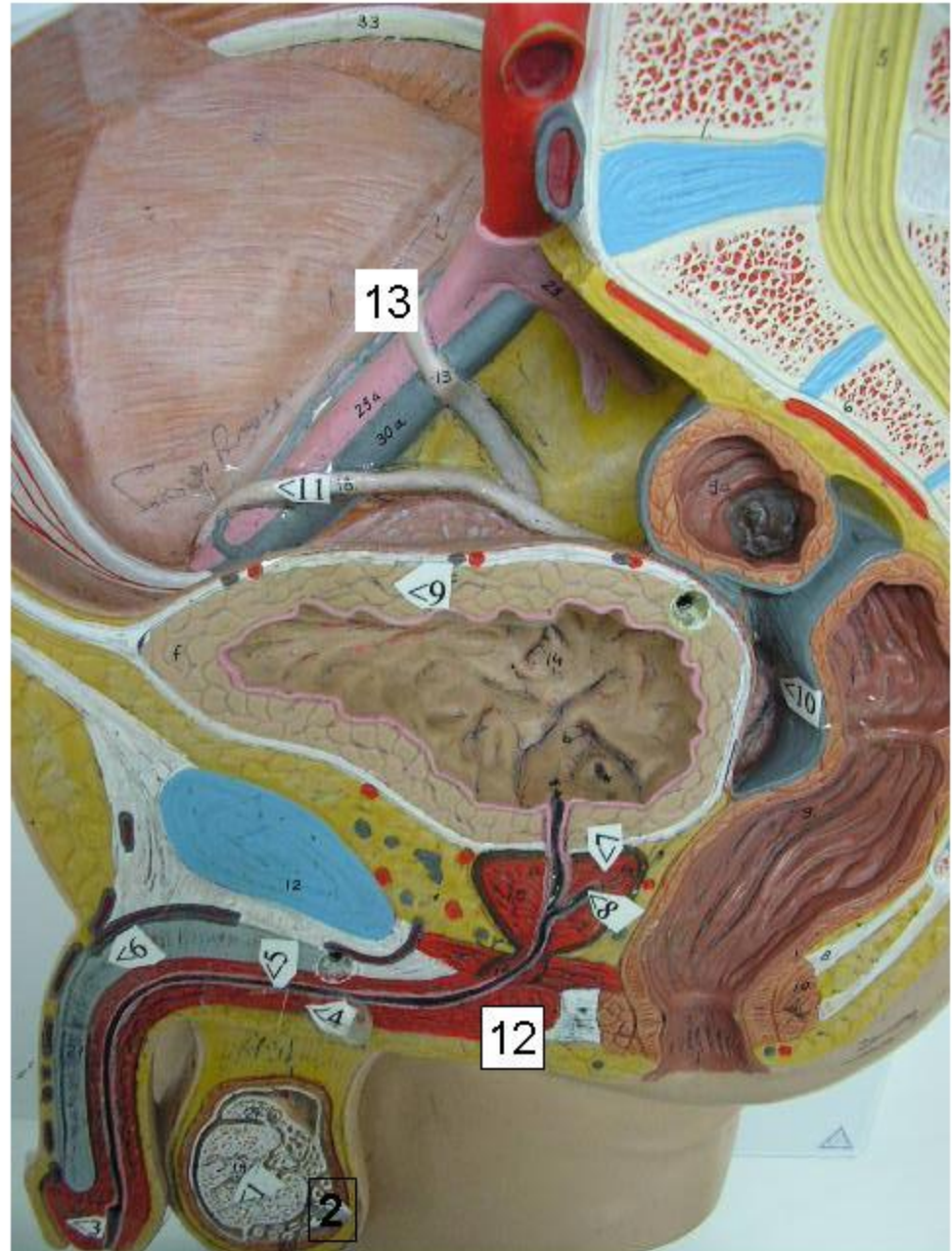
Epididymis

Scrotum





1. Testis
2. Epididymis
3. Glans penis
4. Corpus spongiosum
5. Urethra
6. Corpus cavernosum
7. Prostate gland
8. Ejaculatory duct
9. Urinary bladder
10. Retrovesicle pouch
11. Vas deferens
12. Bulb of penis
13. ureter



1. Ovary
2. Fimbriae
3. Uterine tube
4. Fundus of uterus
5. Body of uterus
6. Cervix
7. Posterior fornix
8. Pouch of Douglas
9. Vagina
10. Lamium minora
11. Lambium majora
12. Round lig. of uterus
13. Ureter
14. Urinary bladder
15. Broad lig.
16. Clitoris

