

---

# The Muscular System (3)

CHAPTER 11

*Dr. Hanan Malkawi*

**Principles of  
Human Anatomy  
13th Edition**

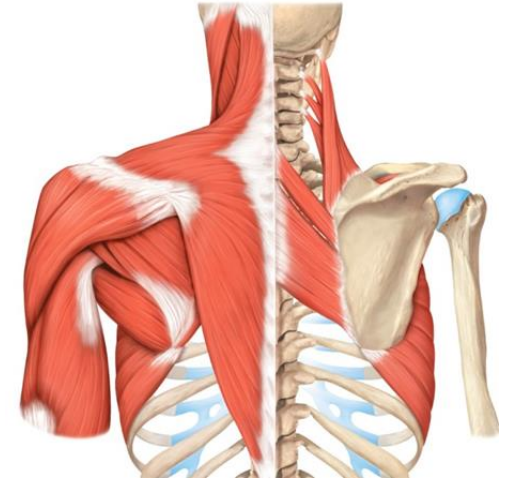
Gerard J. Tortora & Mark T. Nielsen

---

# Muscles of the Thorax That Move the Pectoral( shoulder) Girdle

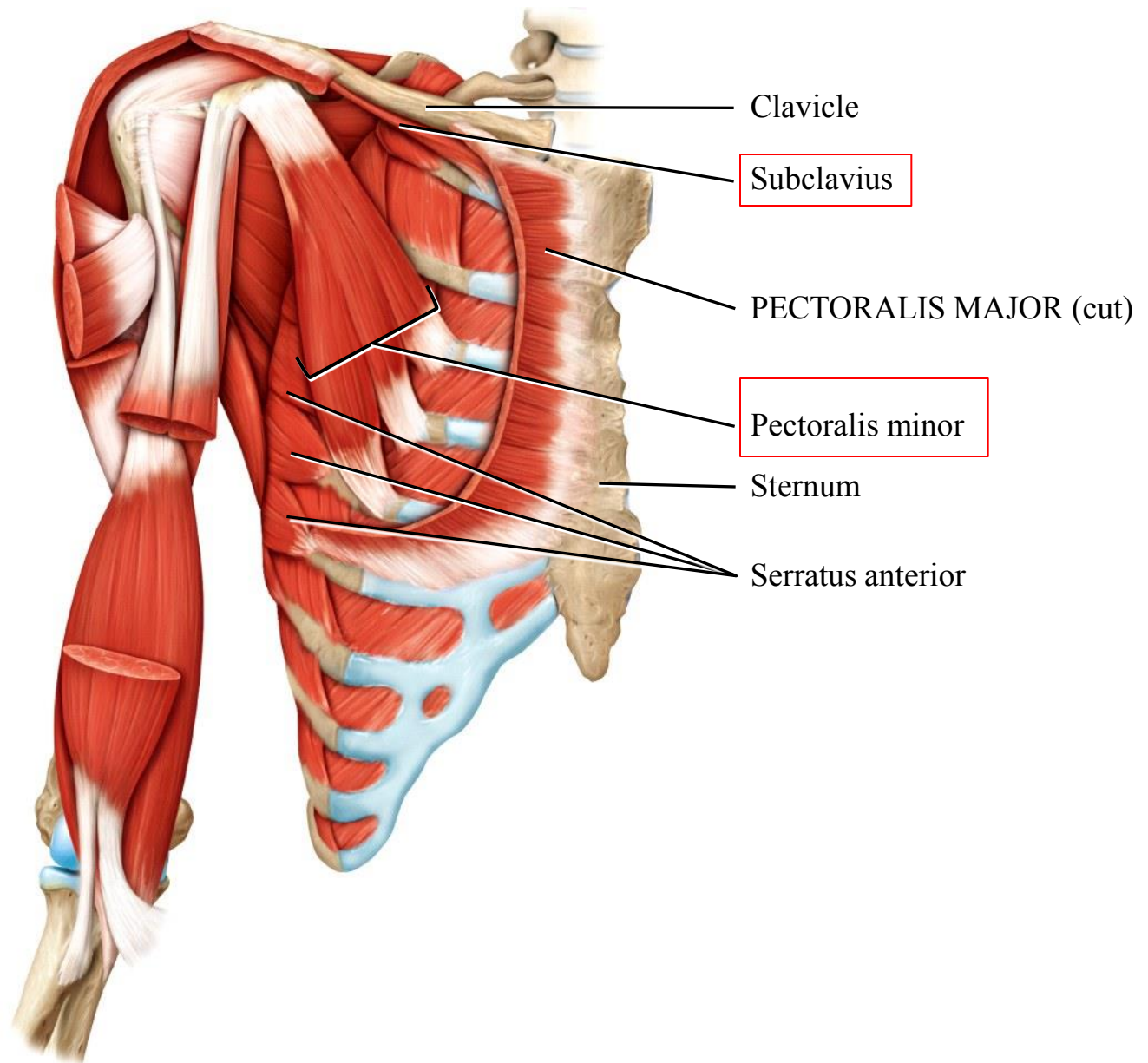
## **Anterior Thoracic muscles:**

1. Subclavius( 1<sup>st</sup> rib- clavicle)
2. Pectoralis minor( ribs- scapula)
3. Serratus anterior(ribs- scapula)

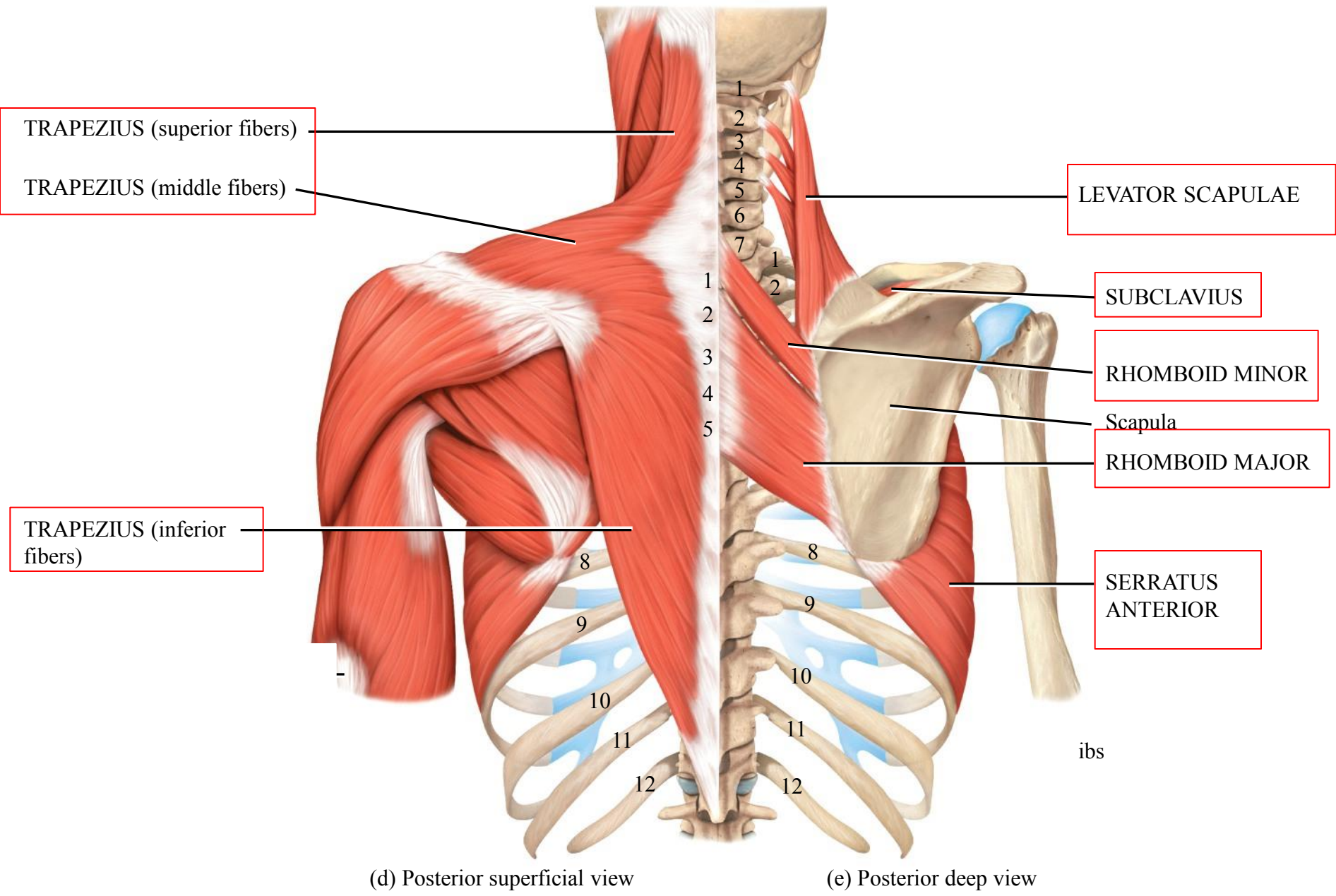


## **Posterior Thoracic muscles:**

1. Trapezius( skull & vertebrae- clavicle & scapula)
2. Levator scapula( vertebrae- scapula)
3. Rhomboid major( vertebrae-scapula)
4. Rhomboid minor( vertebrae- scapula)



(a) Anterior deep view (the intact pectoralis major muscle is shown in [Figure 11.3a](#))



(d) Posterior superficial view

(e) Posterior deep view

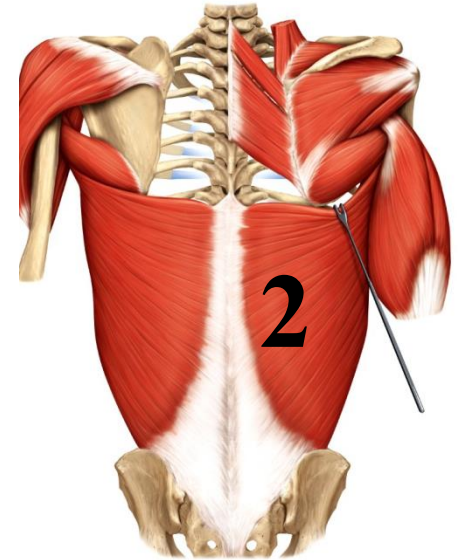
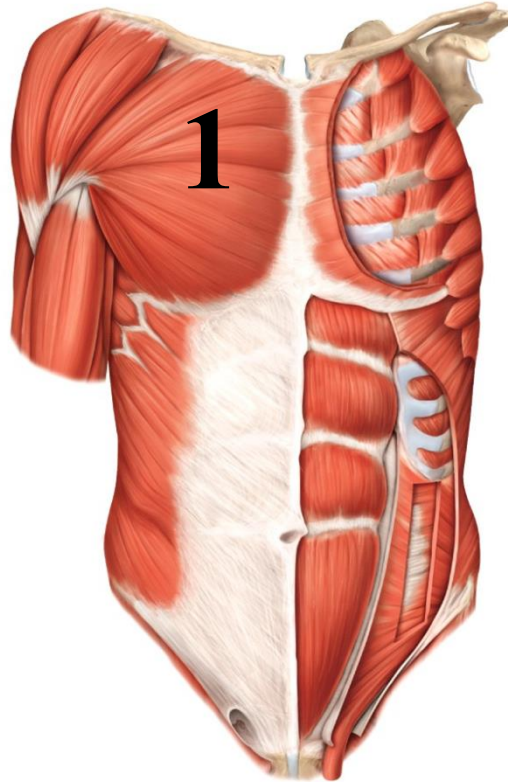
# Muscles of the Thorax and Shoulder That Move the Arm (Humerus)

1. Axial muscles

2. Scapular muscles

# Axial Muscles That Move the Arm (Humerus)

1. **Pectoralis major**
2. **Latissimus dorsi**  
extend from body wall  
to humerus



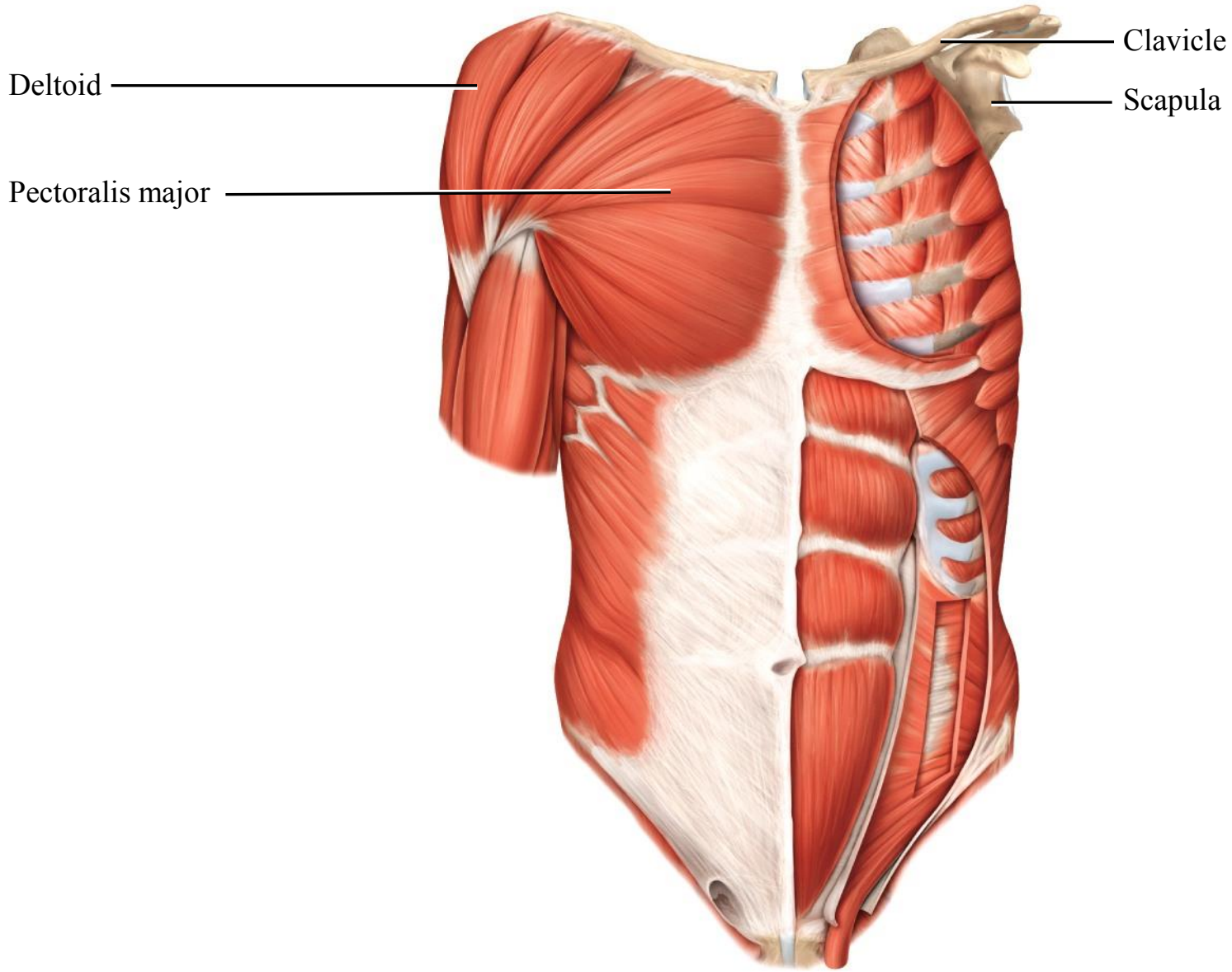
ley & Sons, Inc. All rights reserved.

Action:

Pectoralis major....adduct arm at shoulder joint

Latissimus dorsi .....extend & adduct arm at shoulder joint



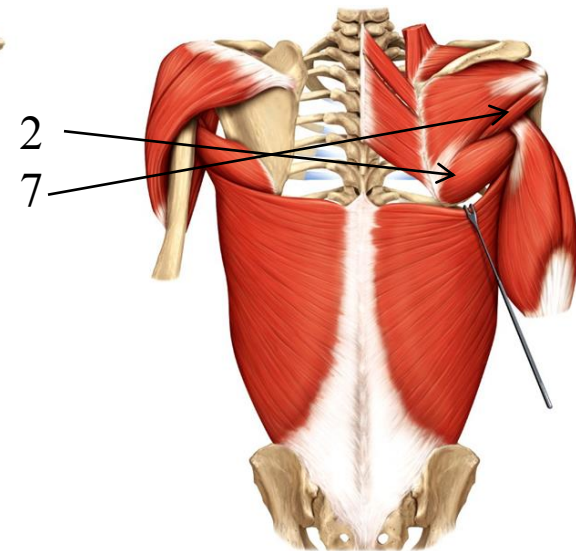
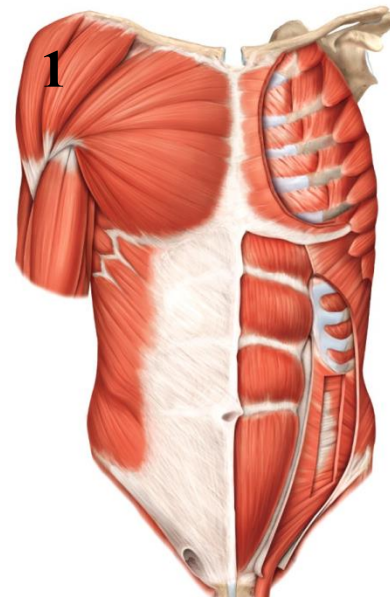
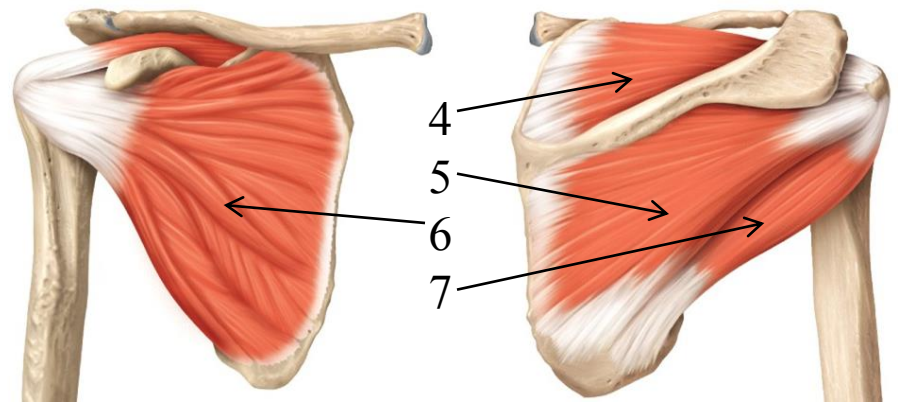


(b) Anterior superficial view

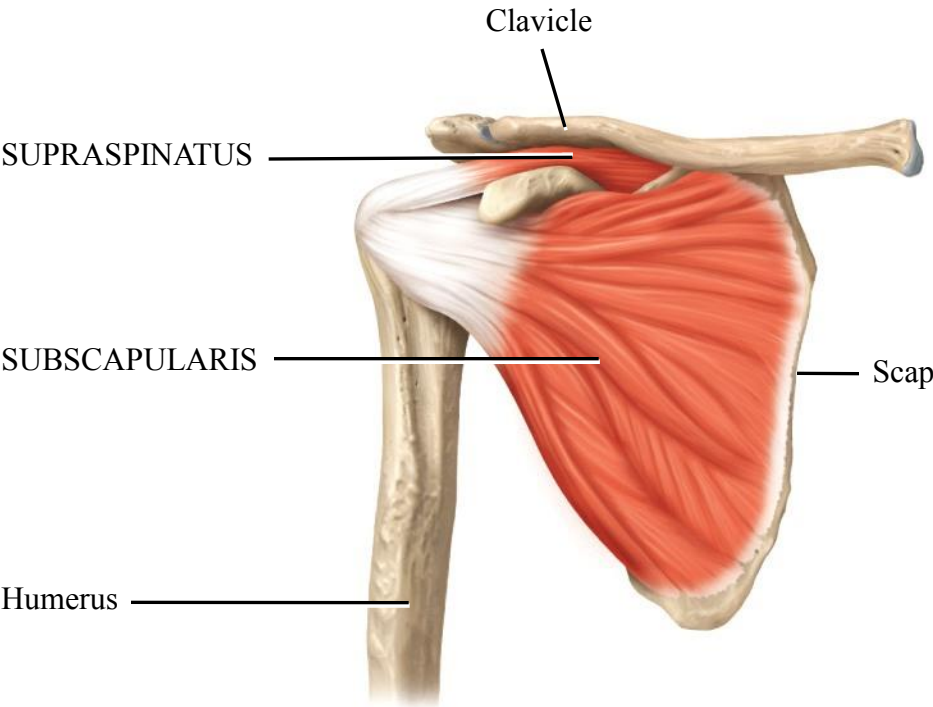
(c) Anterior deep view

# Scapular Muscles That Move the Arm (Humerus)

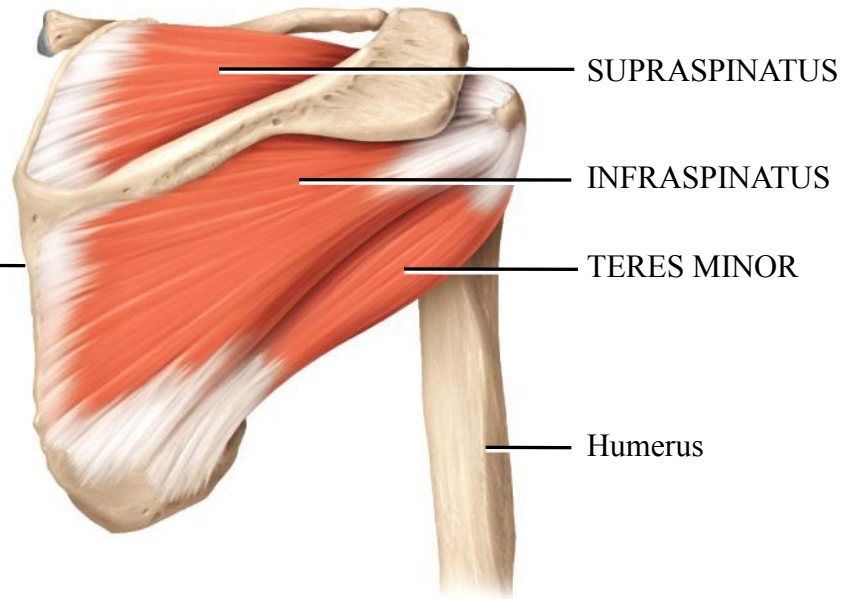
1. Deltoid
2. Teres major
3. Coracobrachialis
4. **Supraspinatus**
5. **Infraspinatus**
6. **Subscapularis**
7. **Teres minor**







(f) Anterior deep view

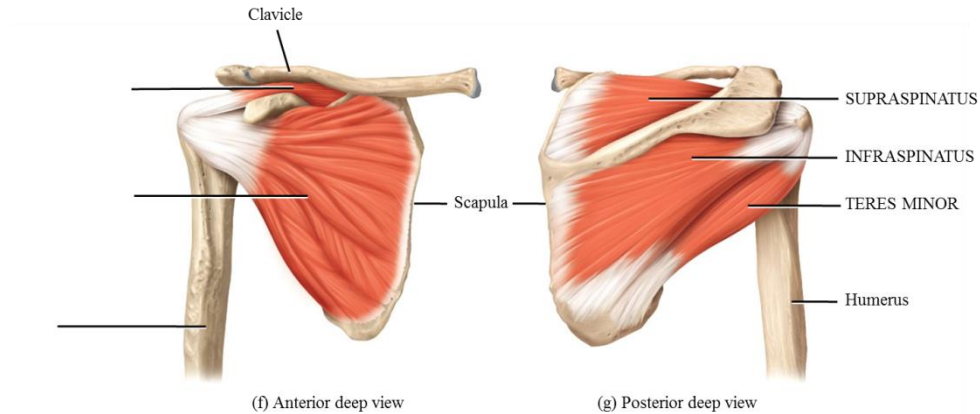


(g) Posterior deep view

Copyright © 2014 John Wiley & Sons, Inc. All rights reserved.

# Rotator cuff muscles

1. Supraspinatus
2. Infraspinatus
3. Subscapularis
4. Teres minor

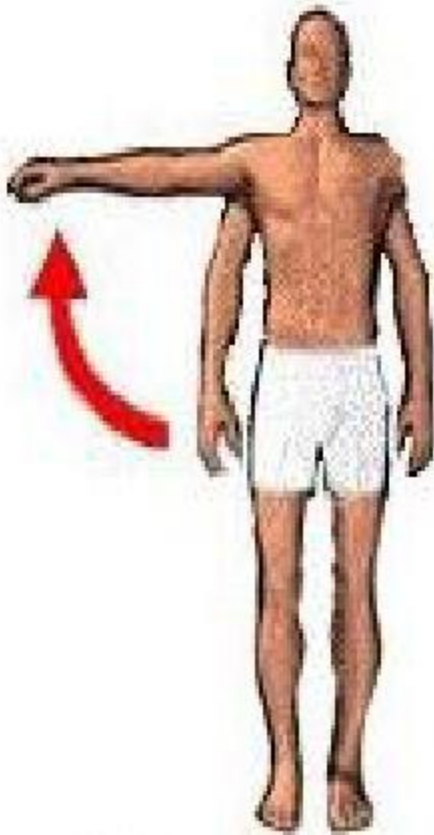


Copyright © 2014 John Wiley & Sons, Inc. All rights reserved.

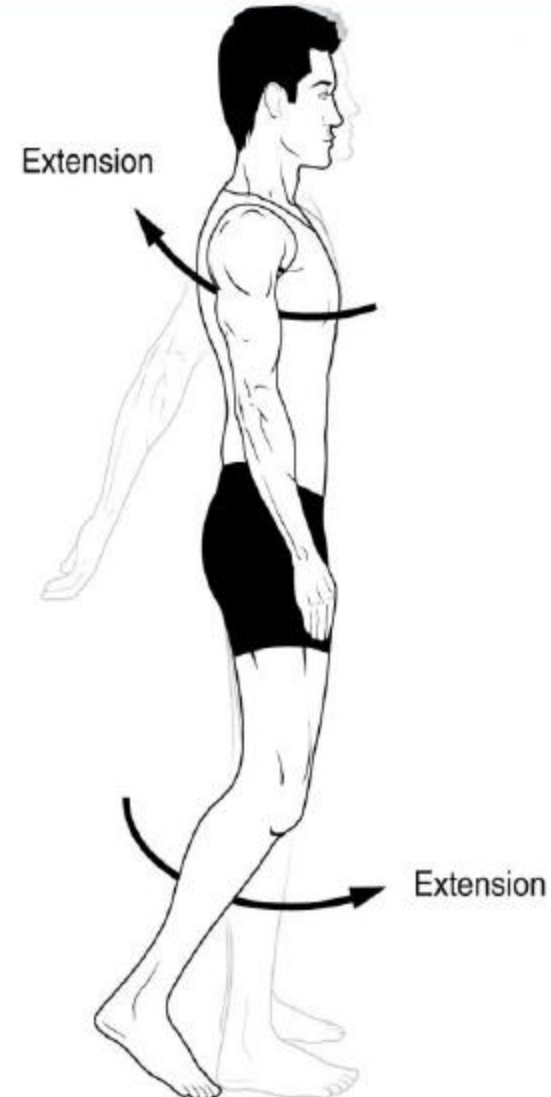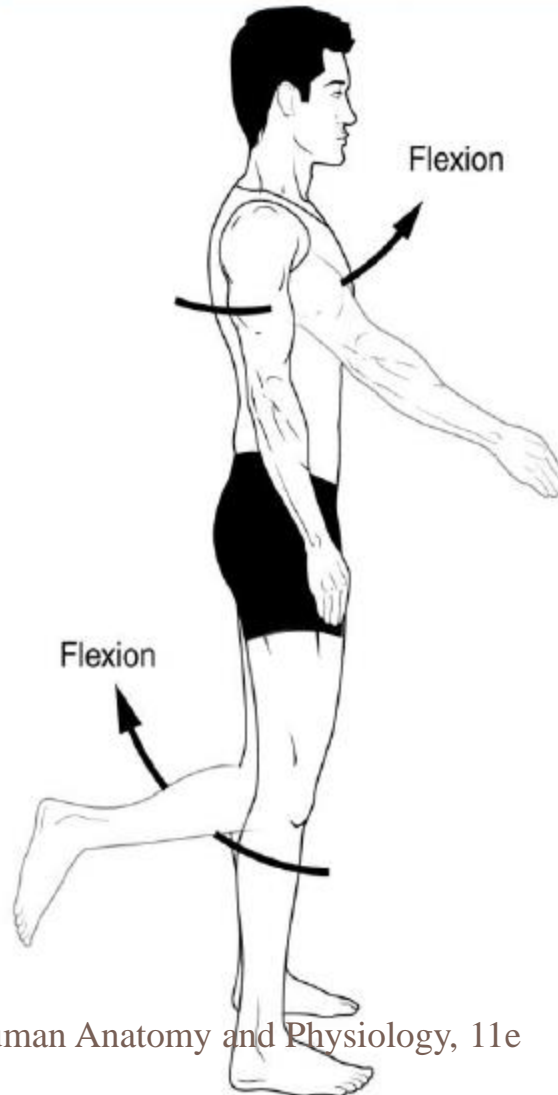
Copyright © 2014 John Wiley & Sons, Inc. All rights reserved.

# Action of deltoid muscle

8



**Abduction**



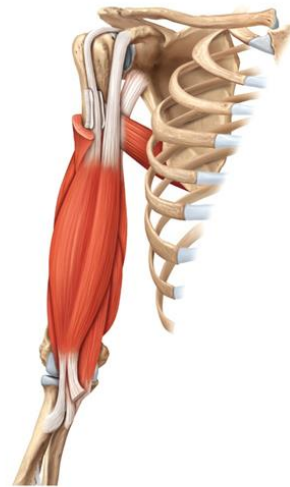
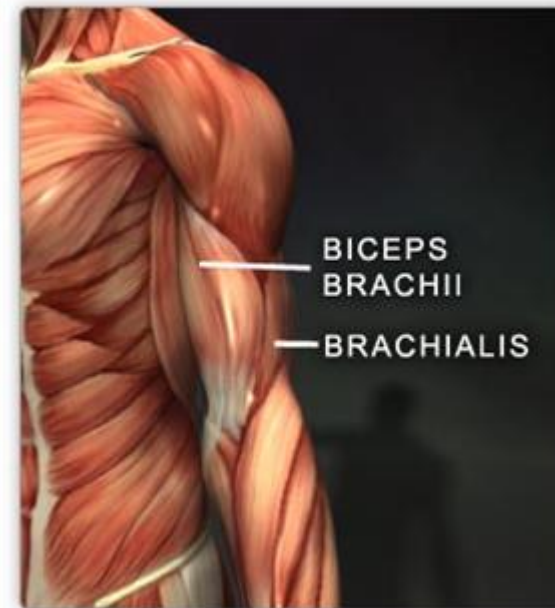
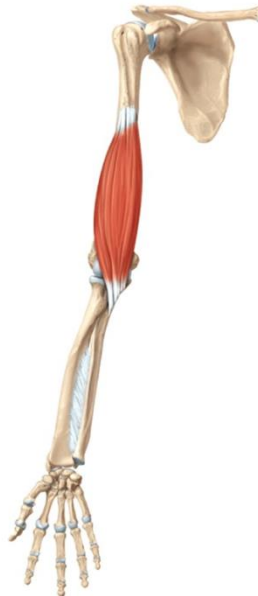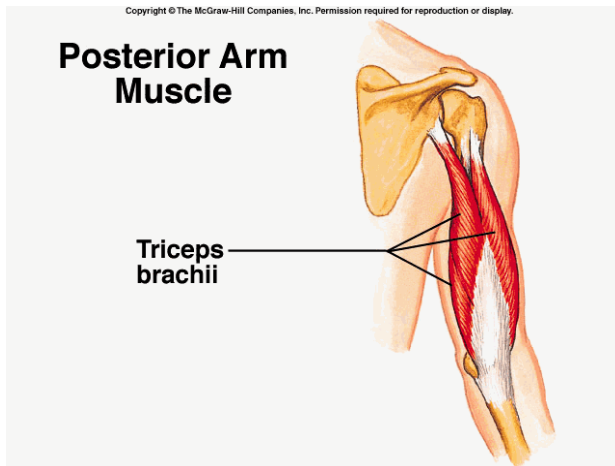
# Muscles of the arm

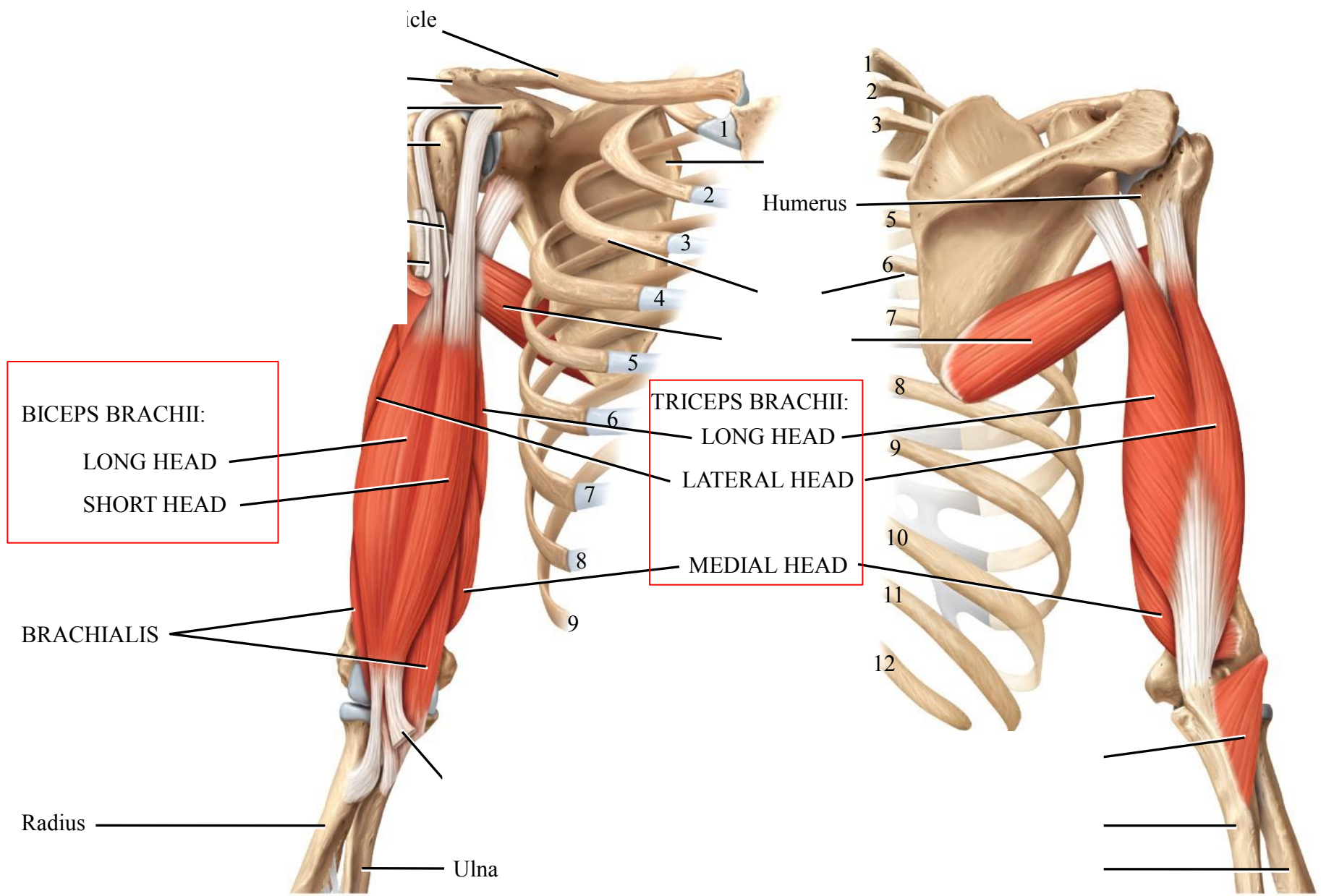
## Anterior:

biceps M. + brachialis M.-----flexion of forearm at elbow jt.

## Posterior:

triceps M.-----extends forearm at elbow jt.

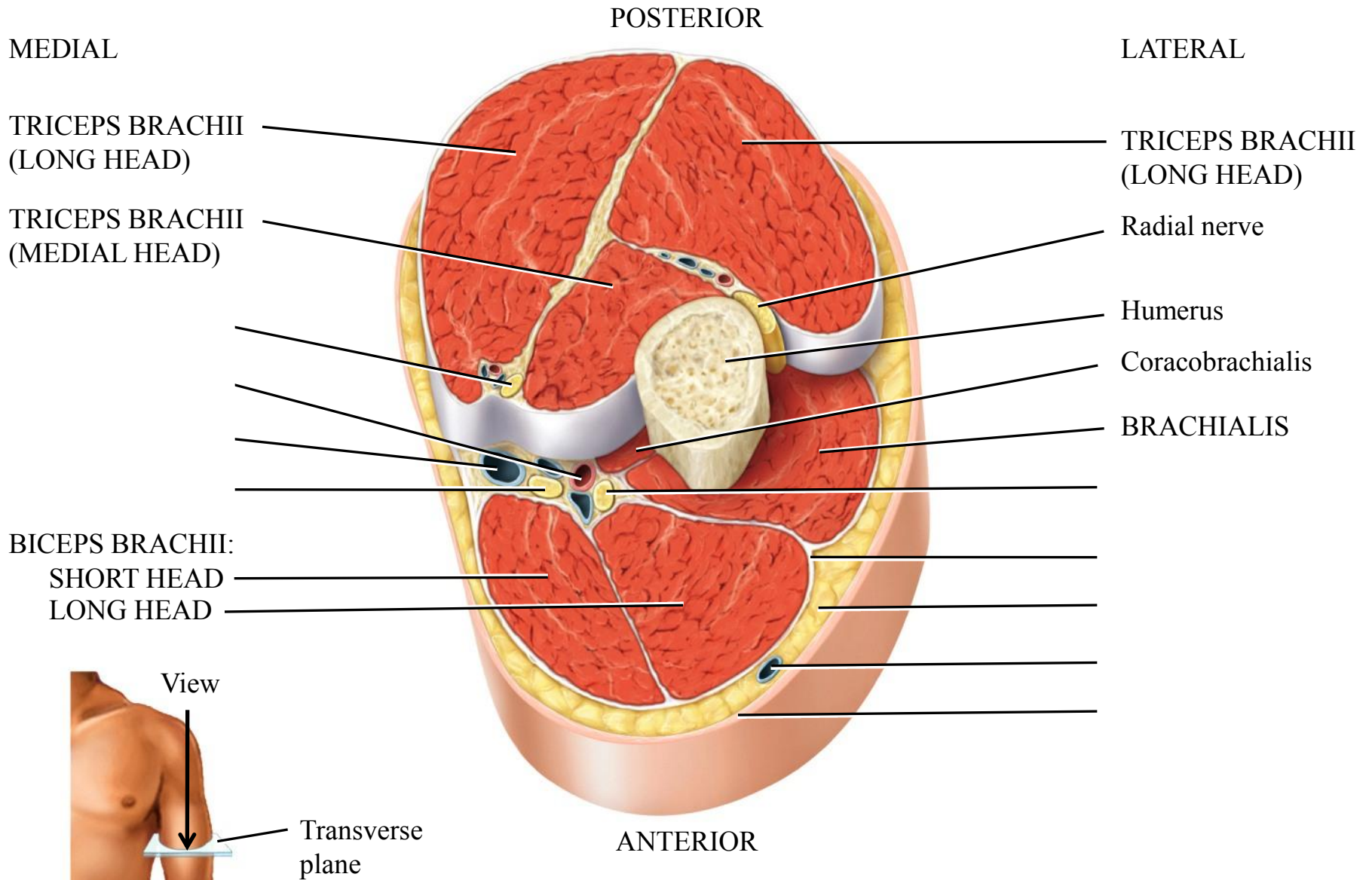




(a) Anterior view

(b) Posterior view





(g) Superior view of transverse section of arm

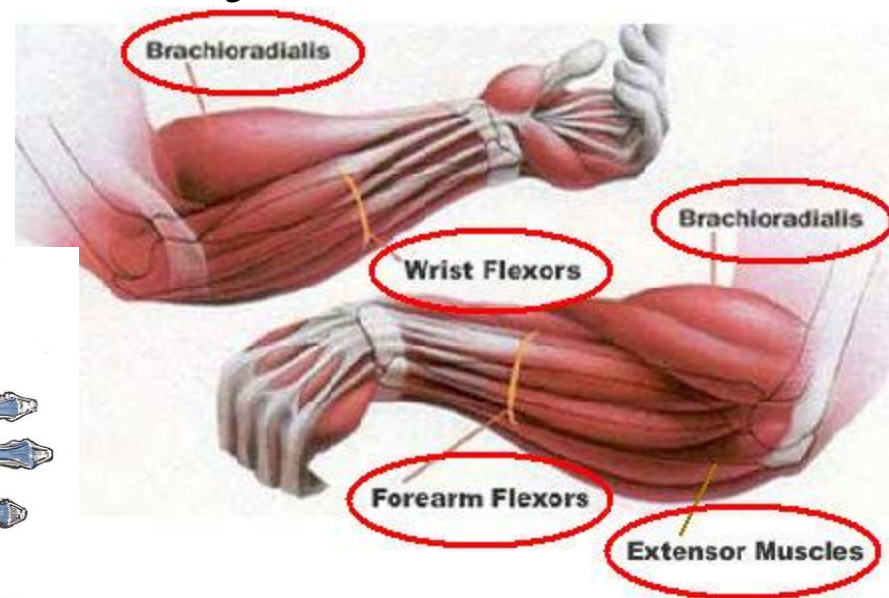
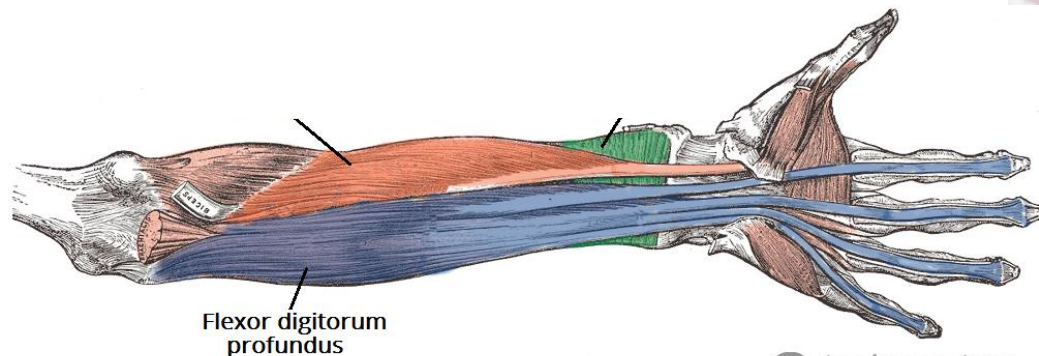
# Muscles of the forearm

## Anterior:

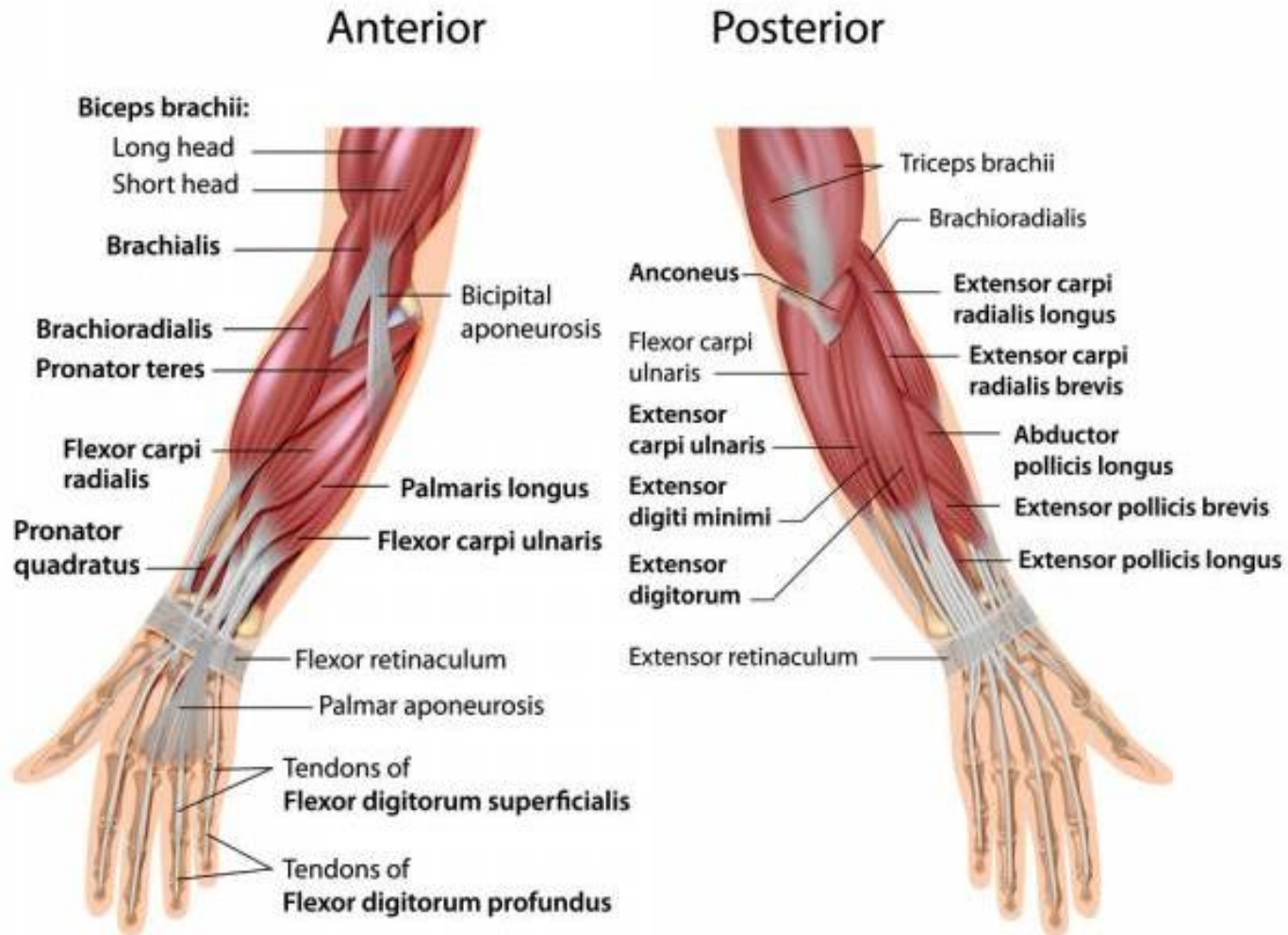
Brachioradialis: flexes forearm at elbow joint.

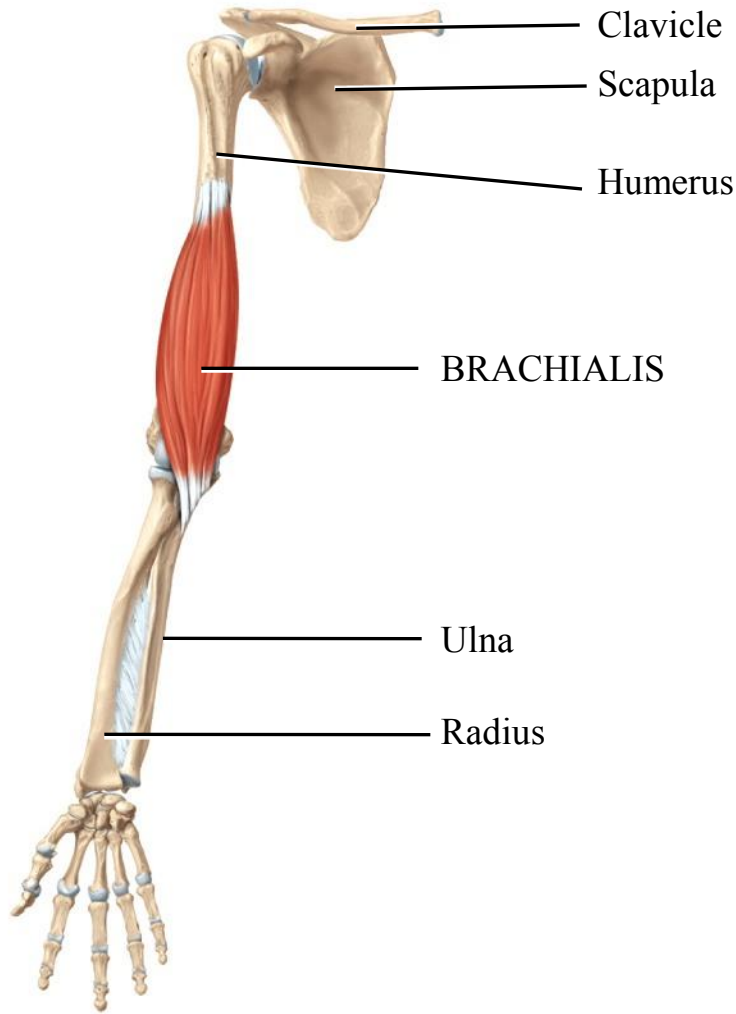
Pronator teres: pronation of forearm

Flexor group: flexes of hand at wrist joint.

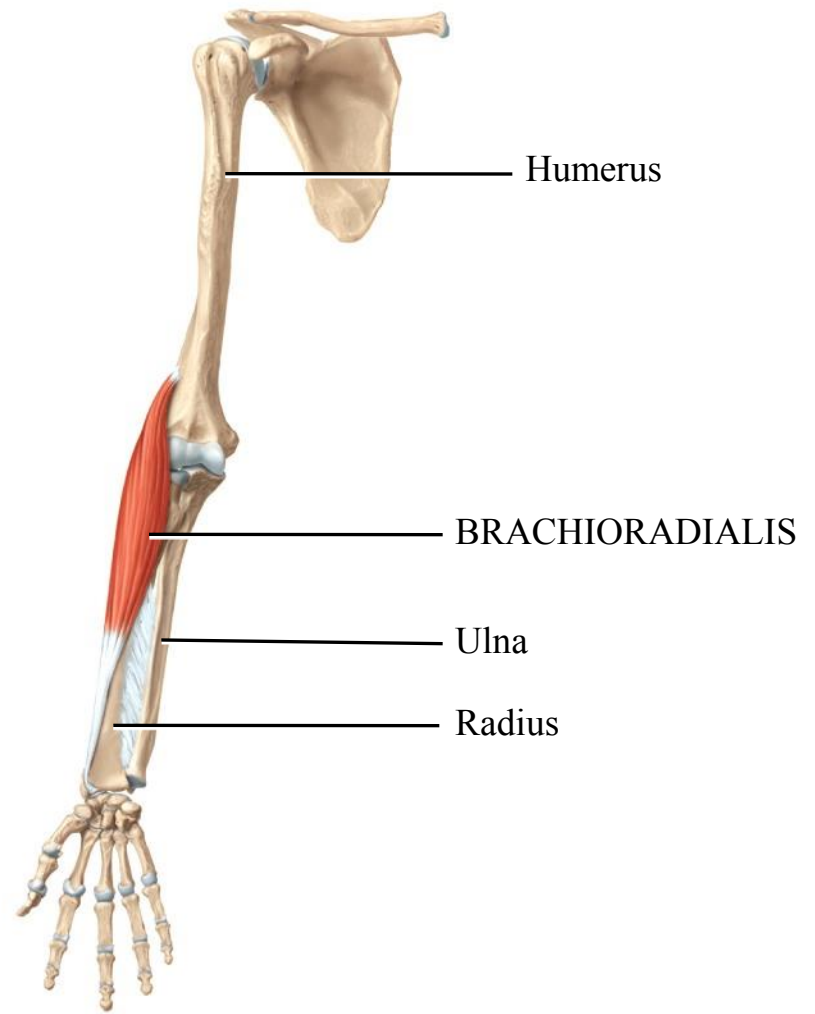


# Muscles of the forearm



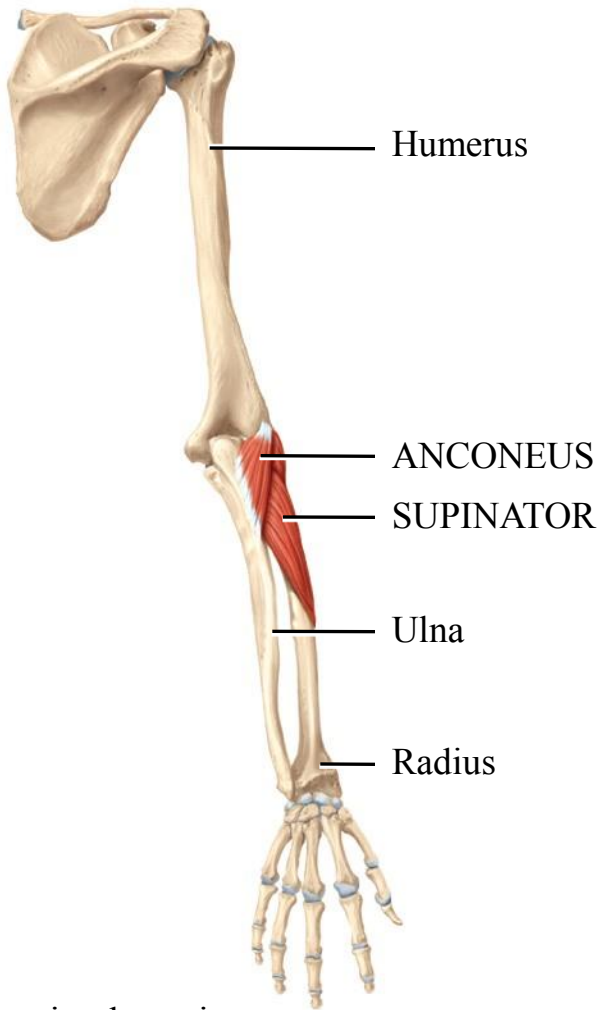


Anterior deep view

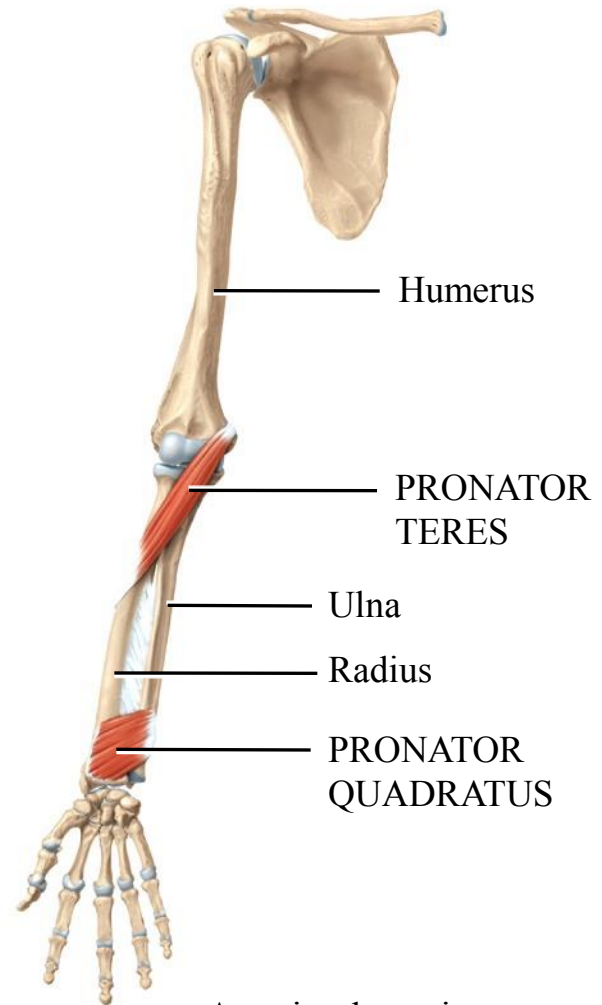


Anterior deep view

Copyright © 2014 John Wiley & Sons, Inc. All rights reserved. (f) Isolated muscles



Posterior deep view



Anterior deep view

(i) Isolated muscles

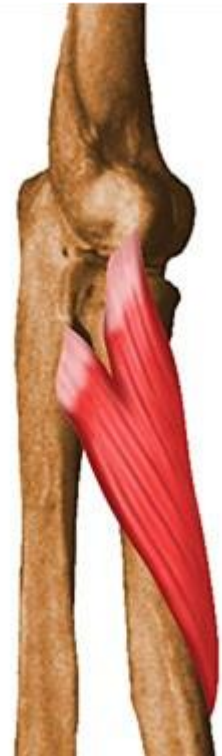

# Muscles of the forearm


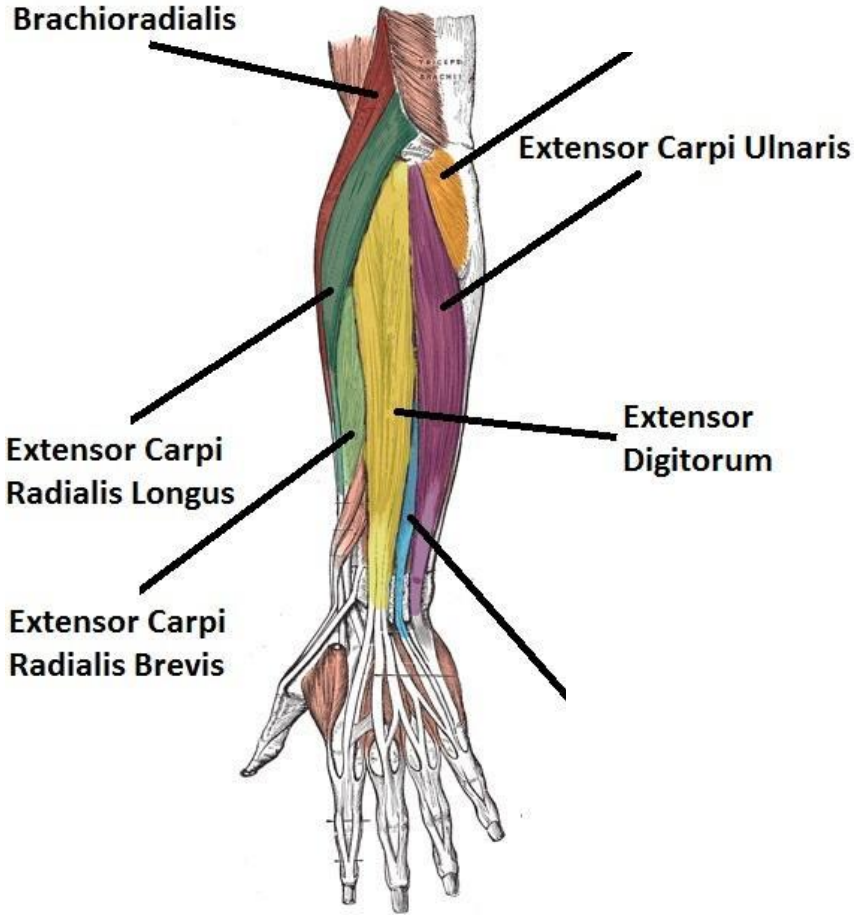
## **posterior:**

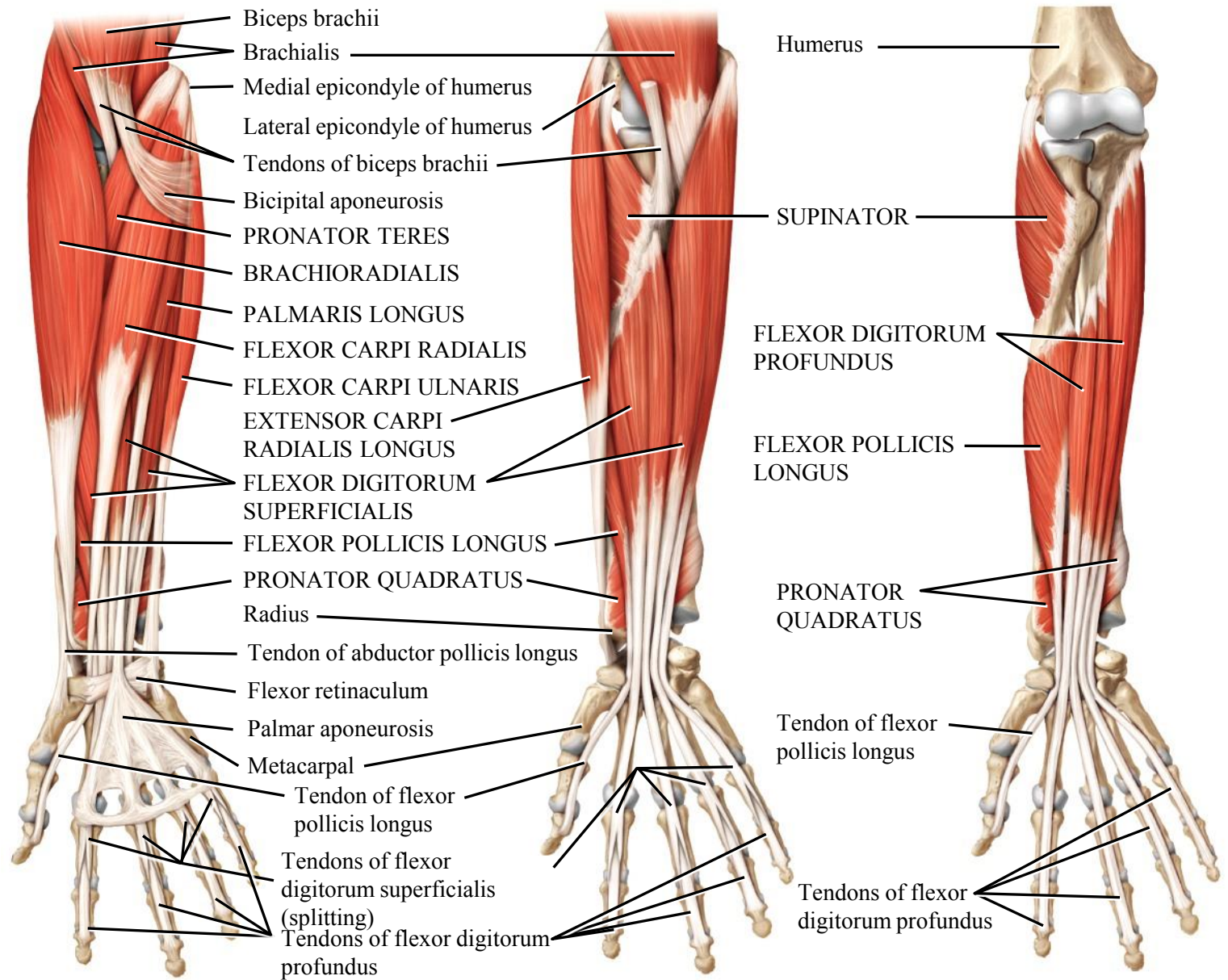
Extensor group of: extension of hand at wrist jt.

Supinator: supination of forearm



# Muscles of the forearm

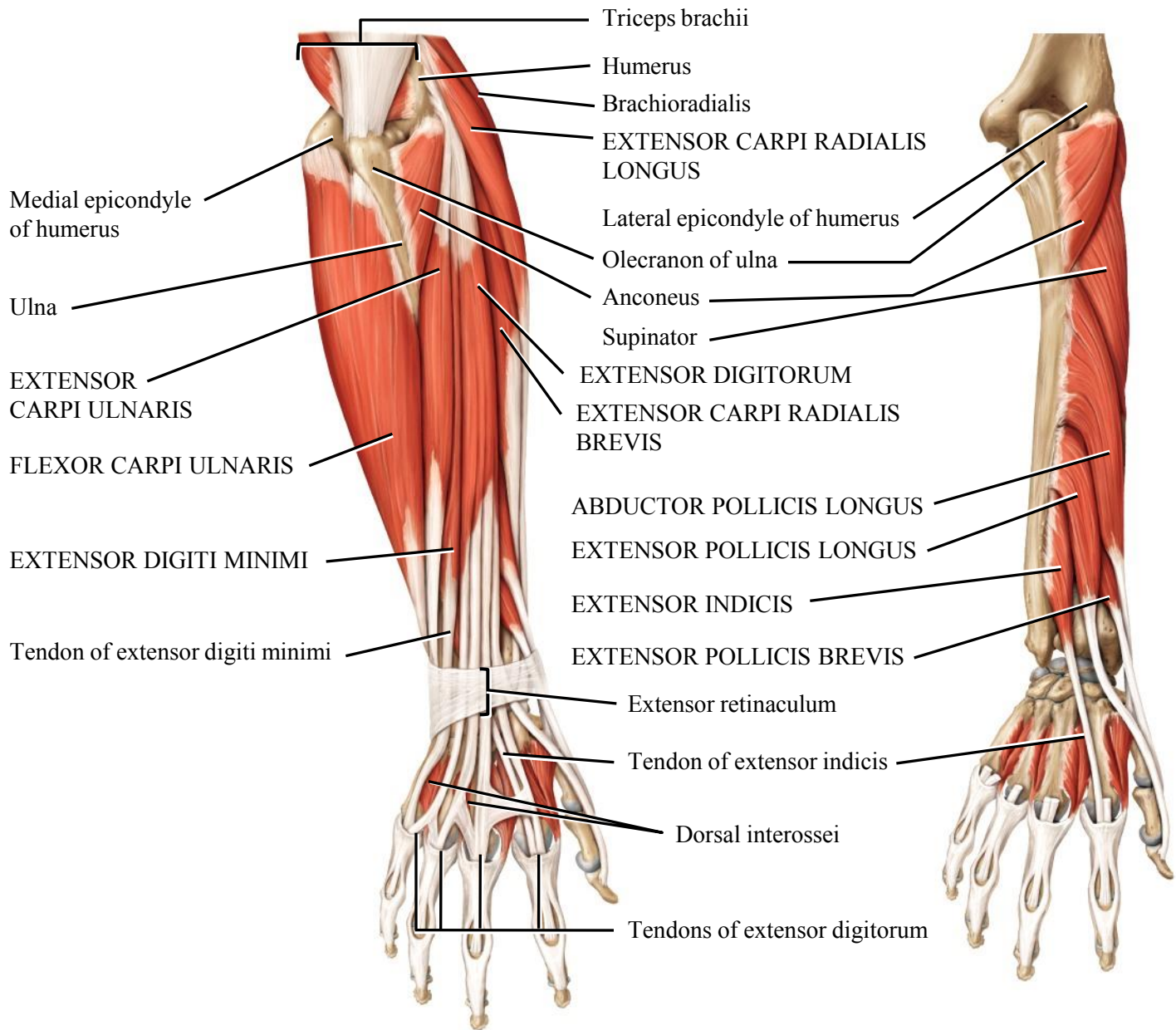




(a) Anterior superficial view

(b) Anterior intermediate view

(c) Anterior deep view



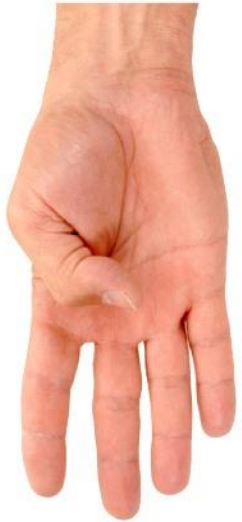(g) Posterior superficial view

(h) Posterior deep view

# Muscles of the hand

- ❖ There are 20 short muscles in the hand
- ❖ 2 important groups
  1. Thenar M.
  2. Hypothenar M.

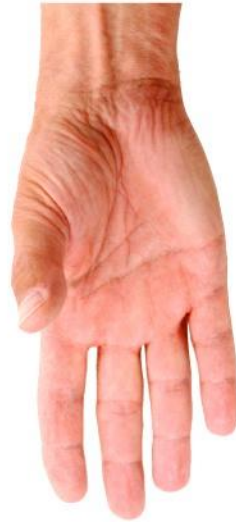



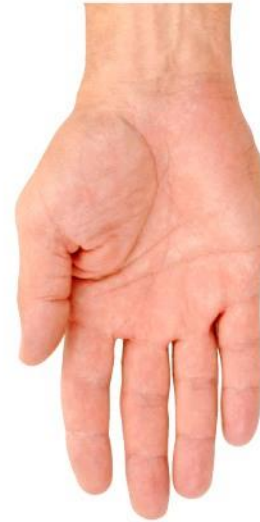Flexion



Extension



Abduction



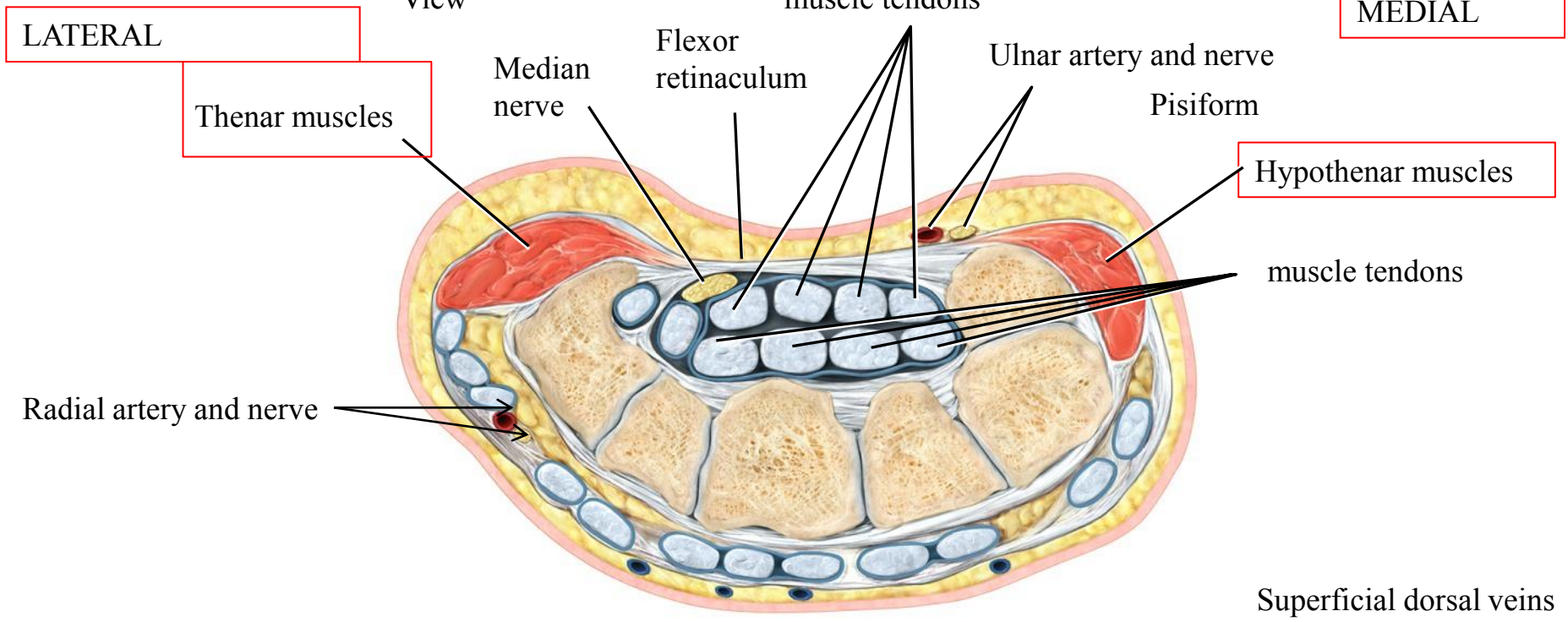
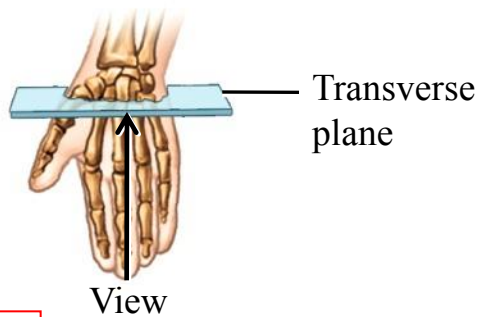
Adduction



Opposition

Andy Washnik

(a) Movements of the thumb



(k) Inferior view of transverse section